

# Laparoscopic management of testicular tumour in undescended intra-abdominal testis with torsion

Deep Goel, Sanjay Aggarwal, A. Sadana, C. S. Ramachandran  
and Vijay Arora

*Department of General and Laparoscopic Surgery, Sir Ganga Ram Hospital,  
New Delhi, India*

Date accepted for publication 12 January 2004

## Abstract

Testicular tumours occur more frequently in an undescended testis than in a normally developed testis. Moreover, they usually present as a palpable mass but occasionally they can present with pain as a result of torsion. We present the case of a 30-year-old male who was found to have a testicular tumour which had developed in an intra-abdominal testis and presented with pain as the main symptom. Based on clinical and radiological data, orchidectomy was then carried out laparoscopically. Laparoscopy is a very useful tool for accurate diagnosis and therapeutic surgery in such cases resulting in quicker recovery than after open surgery.

Abstract

Keywords

Introduction

Surgical procedure

Clinical evidence

Lesson

References

Figure 1

Figure 2

Home Page

Title Page



Go Back

Full Screen

Close

Quit

GR

## Keywords

Intra-abdominal testis; tumour; torsion; laparoscopy.

## Introduction

A 30-year-old man presented to us with acute pain in the lower abdomen. There were no associated urinary or bowel complaints. On examination, the patient was found to have a normal left testis and an absent right testis. No lump was palpable on abdominal examination. There was no tenderness. The scrotum on the right side was under-developed. The hernial orifices were normal. He had been married for 6 years and had two children. Ultrasound showed a mass  $8 \times 8$  cm in size in the right lower abdomen. A CT scan of the abdomen showed a  $10 \times 8$  cm mass with cystic and solid components in the lower abdomen (Fig. 1). The rest of the abdominal viscera and the retroperitoneum were normal. A diagnosis of a testicular tumour in an intra-abdominal testis was considered and the patient was further investigated. The human beta-subunit chorionic gonadotropin ( $\beta$ HCG) was marginally raised [HCG 18 IU/ml (normal  $<10$  IU/ml)]. The alpha-fetoprotein was normal [4 IU/ml (normal  $<10$  IU/ml)].

## Surgical procedure

The patient underwent a diagnostic laparoscopy. A 10 mm infra-umbilical incision was made for the camera port and a 5 mm incision was made at the junction of the left spino-umbilical line and the left midclavicular line for a second port. A third 5 mm incision was made 10 cm below the second port in the left midclavicular line for a third port. On diagnostic laparoscopy, a  $10 \times 8$  cm testicular mass with a variegated appearance with an attached torted cord was present in the right lower abdomen (Fig. 2).

The spermatic cord was ligated and divided. The mass was dissected free from the surrounding tissue and removed inside an Endobag. Post-operative recovery was uneventful and the patient was discharged on the second post-operative day.

[Abstract](#)

[Keywords](#)

[Introduction](#)

[Surgical procedure](#)

[Clinical evidence](#)

[Lesson](#)

[References](#)

[Figure 1](#)

[Figure 2](#)

[Home Page](#)

[Title Page](#)

[◀◀](#) [▶▶](#)

[◀](#) [▶](#)

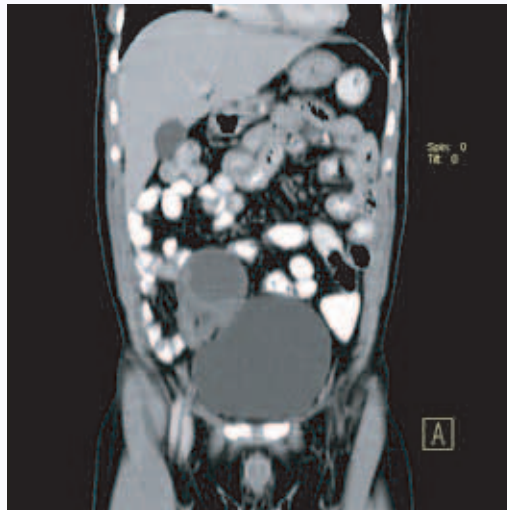
[Go Back](#)

[Full Screen](#)

[Close](#)

[Quit](#)

GR



**Fig. 1.** CT Scan showing testicular tumor in right lower abdomen.

Macroscopic examination revealed a tense cystic mass with an attached spermatic cord. The cyst measured  $8 \times 6 \times 4$  cm. The cystic portion was filled with a necrotic cheesy greyish white material. The cyst wall thickness varied between 0.1 and 0.4 cm. Greyish-black compressed testicular tissue was present in the wall. Microscopic examination revealed a mature cystic teratoma. The cyst was lined by stratified squamous epithelium and filled with keratin. There was pressure atrophy of the testicular tissue. There were foci of hemosiderin deposits, haemorrhage and congestion in the tissue. There was no malignant transformation.

At 2 year follow-up there was no recurrence or lymphadenopathy. An ultrasound carried out in August 2003 was normal.

**Abstract**

**Keywords**

**Introduction**

**Surgical procedure**

**Clinical evidence**

**Lesson**

**References**

[Figure 1](#)

[Figure 2](#)

[Home Page](#)

[Title Page](#)

◀

▶

◀

▶

[Go Back](#)

[Full Screen](#)

[Close](#)

[Quit](#)

GR

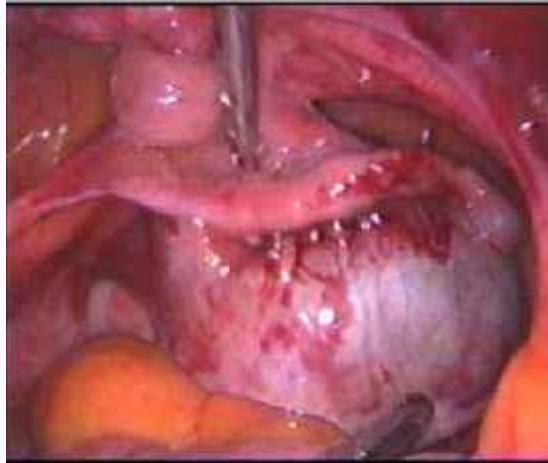


Fig. 2. Laparoscopic view of the testicular tumor with torsion.

## Clinical evidence

Very few cases of torsion of an intra-abdominal testis containing tumour have been reported in the literature. All of them were managed by open surgery. Seminomas and, less frequently, embryonal cell carcinoma are the two most frequent neoplasms encountered in cryptorchid testes. Occasionally, a teratoma of the intra-abdominal testes is encountered. Recent improvements in surgical techniques, including laparoscopic approaches to diagnosis and treatment, hold the promise of an improved outcome<sup>[1,2]</sup>. The first case reported was by Gerster in 1897. Rigler found that 64% of adults with torsion in an undescended testis had an associated germ cell tumour. Subsequently, sporadic cases have appeared in the literature<sup>[3,4]</sup>. Few cases are reported where laparoscopic orchidectomy has been performed for intra-abdominal testis with torsion, but without tumour<sup>[5]</sup>.

[Abstract](#)

[Keywords](#)

[Introduction](#)

[Surgical procedure](#)

[Clinical evidence](#)

[Lesson](#)

[References](#)

[Figure 1](#)

[Figure 2](#)

[Home Page](#)

[Title Page](#)

◀

▶

◀

▶

[Go Back](#)

[Full Screen](#)

[Close](#)

[Quit](#)

GR

## Lesson

This case illustrates not only the unusual presentation of a testicular tumour, which was diagnosed preoperatively on investigation, but also establishes the role of therapeutic laparoscopy in the management of such cases. Laparoscopy was sufficient to exclude other causes of acute abdominal pain. It allows the safe dissection and removal of an intra-abdominal testis along with all the advantages of a laparoscopic procedure like cosmesis, reduced pain, and quicker recovery of the patient. We therefore recommend a first line laparoscopic approach in all such cases of complicated undescended testis as a means of both diagnosis and definitive therapy.

## References

1. Mukai M, Takamastu H, Noguchi H, Tahara H. Intra-abdominal testis with mature teratoma. *Pediatr Surg Int* 1998; 13(2-3): 204-5.
2. Docimo SG, Silver RI, Cromie W. The undescended testicle: diagnosis and management. *Am Fam Physician* 2000; 62(9): 2037-44, 2047-8 (review).
3. Osamu D, Fumio I, Koji A. Mature teratoma arising in intraabdominal undescendedtestis in an infant with previous inguinal exploration: casereport and review of intraabdominal testicular tumours inchildren. *J Pediatr Surg* 2002; 37(8): 1236-8.
4. Memon AS, Siddiqui FG. Cryptorchid testicular tumour presenting with torsion. *J Coll Physicians Surg Pak* 2003; 13(2): 118-9.
5. Lee KF, Tang YC, Leong HT. Emergency laparoscopic orchidectomy for torsion ofintra-abdominal testis. *JR Coll Surg Edinb* 2001; 46(2): 110-2.

[Abstract](#)[Keywords](#)[Introduction](#)[Surgical procedure](#)[Clinical evidence](#)[Lesson](#)[References](#)[Figure 1](#)[Figure 2](#)[Home Page](#)[Title Page](#)[Go Back](#)[Full Screen](#)[Close](#)[Quit](#)