

Grand Rounds Vol 3
Speciality: Trauma
Article Type: Case report
DOI: 10.1102/1470-5206.2003.0009
© 2003 e-MED Ltd

Penetrating gunshot injury to the chest with unusual intraluminal passage of the bullet

C. J. Desai and R. R. Hutchins

Department of Hepatopancreaticobiliary, Upper Gastrointestinal and Trauma Surgery, The Royal London Hospital, Whitechapel, London, UK

Date accepted for publication 14 October 2003

Abstract

The authors present an unusual case of penetrating chest trauma. This serves to remind clinicians that all possibilities should be considered when managing trauma victims and that seemingly serious injuries are increasingly treated in a conservative manner with a successful outcome.

Keywords

Penetrating chest trauma; bullet wounds; oesophageal injury.

[Abstract](#)

[Keywords](#)

[Introduction](#)

[Case report](#)

[Discussion](#)

[Learning point](#)

[References](#)

[Figure 1](#)

[Figure 2](#)

[Figure 3](#)

[Figure 4](#)

[Home Page](#)

[Title Page](#)

[◀](#) [▶](#)

[◀](#) [▶](#)

[Go Back](#)

[Full Screen](#)

[Close](#)

[Quit](#)

GR

Introduction

Gunshot injuries are increasing in frequency in the UK. Injuries to the mediastinum have a wide spectrum of clinical sequelae ranging from no clinical significance to immediate death^[1,2]. A case is reported of a 26-year-old man with a gunshot injury to the chest. The patient passed the bullet in his stool 4 days later with no significant adverse clinical outcome. This case is interesting because it is not clear when and how the bullet entered the lumen of the gastrointestinal tract.

Case report

A 26-year-old man was brought to the Accident & Emergency department of a local district general hospital, having been shot from behind. On arrival he had an entry wound 1 cm in diameter on the right side of the back of his chest between the spinous process of T7 and the angle of the scapula. There was no obvious exit wound. There was no active bleeding or other evident injury. On primary survey, he was conscious and co-operative. He was haemodynamically stable with a pulse of 70 and blood pressure of 170/95 mmHg. Oxygen saturation (SaO₂) was 100% on room air and the Glasgow Coma Scale (GCS) was 15/15. On secondary survey, he had bilateral normal and equal air entry, normal heart sounds and a soft, non-tender abdomen. He was admitted for further evaluation and observation. On admission all blood tests were within normal limits (full blood count, urea and electrolytes, liver function tests and coagulation screen). A plain abdominal X-ray showed the bullet at the level of the L3 vertebra (Fig. 1). A plain abdominal X-ray performed a few hours later showed an opacity consistent with a bullet in the right iliac fossa suggesting passage of the projectile, possibly via the lumen of the gastrointestinal tract (Fig. 2). A CT scan of the abdomen and chest was performed to gain more information, which showed a linear gunshot tract running in the medial aspect of the right lower lobe of the lung (Fig. 3). There was also a small pneumomediastinum and haemopneumothorax on the right side. The bullet in this CT examination was seen in the right iliac fossa seemingly within the

[Abstract](#)[Keywords](#)[Introduction](#)[Case report](#)[Discussion](#)[Learning point](#)[References](#)[Figure 1](#)[Figure 2](#)[Figure 3](#)[Figure 4](#)[Home Page](#)[Title Page](#)[◀](#)[▶](#)[◀](#)[▶](#)[Go Back](#)[Full Screen](#)[Close](#)[Quit](#)

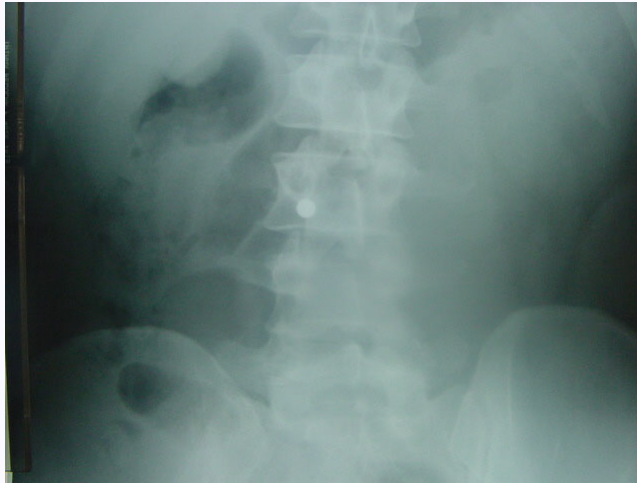

Fig. 1. Plain abdominal X-ray demonstrating bullet at L3 level.

lumen of the caecum (Fig. 4). All the intra-abdominal organs were normal. During this period of observation he remained stable but reported one episode of minor haemoptysis. He was transferred to a level 1 trauma centre with a possible diagnosis of perforation of the oesophagus. A water soluble contrast study of the oesophagus and stomach was performed. There was free flow of contrast into the small bowel and no evidence of an oesophageal leak. The CT scan was reviewed and the results of the earlier study were confirmed. He remained well clinically and tolerated an oral intake well. Four days later a bullet was recovered from his stool, confirming its presence within the gastrointestinal tract, and was preserved for forensic examination. He was discharged the following day. He has remained well since.

[Abstract](#)

[Keywords](#)

[Introduction](#)

[Case report](#)

[Discussion](#)

[Learning point](#)

[References](#)

[Figure 1](#)

[Figure 2](#)

[Figure 3](#)

[Figure 4](#)

[Home Page](#)

[Title Page](#)

[◀◀](#) [▶▶](#)

[◀](#) [▶](#)

[Go Back](#)

[Full Screen](#)

[Close](#)

[Quit](#)

GR

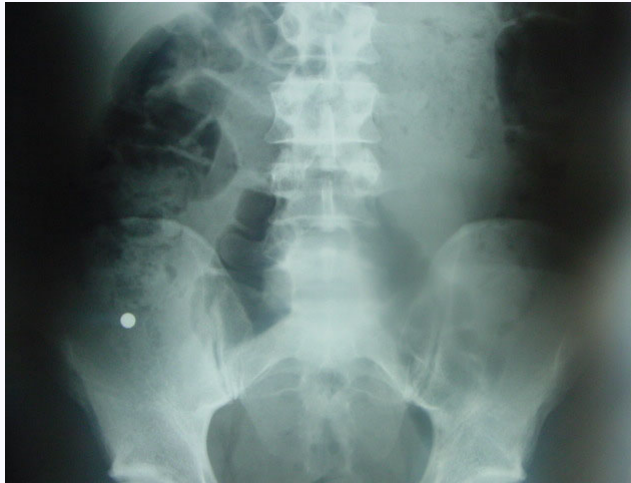

Fig. 2. Plain abdominal film showing migration of bullet to the right iliac fossa.

Discussion

Gunshot wounds that traverse the mediastinum frequently cause serious injury to the cardiac, vascular, pulmonary and digestive structures contained within. Most patients either die immediately or present with unstable vital signs signifying the need for emergency operation^[3]. Occasionally patients will present with stable vital signs. These 'stable' patients can be uninjured, may have sustained contained vascular injuries or may have injuries to the oesophagus or tracheobronchial tree^[1]. There is no difference in vital signs or blood gas examination to indicate which patients presenting in a stable condition will go on to have serious injury^[3]. Close clinical observation and methodical investigation are advocated to avoid missing an injury with disastrous consequences.

[Abstract](#)

[Keywords](#)

[Introduction](#)

[Case report](#)

[Discussion](#)

[Learning point](#)

[References](#)

[Figure 1](#)

[Figure 2](#)

[Figure 3](#)

[Figure 4](#)

[Home Page](#)

[Title Page](#)

◀◀ ▶▶

◀ ▶

[Go Back](#)

[Full Screen](#)

[Close](#)

[Quit](#)

GR

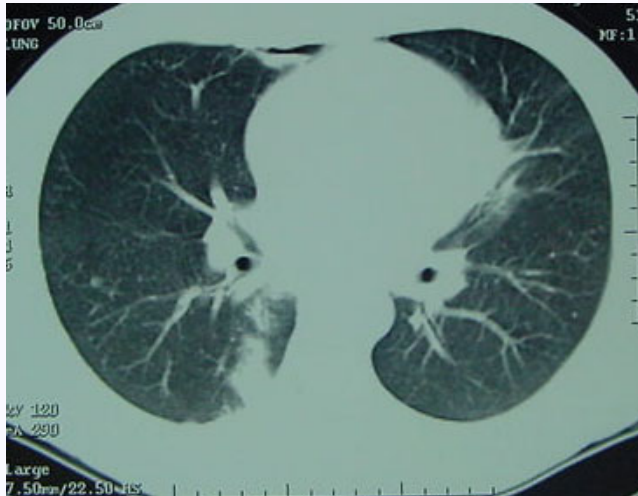

Fig. 3. CT chest with gunshot tract seen in right lung base.

Investigation of these patients includes chest X-ray, US scan, CT scan of the chest and abdomen and organ specific investigations. The plain chest X-ray shows the location of the bullet, heart size, pneumomediastinum, pneumothorax or haemothorax. The US scan helps detect cardiac tamponade as well as abdominal solid organ injury associated with travel of the projectile. In haemodynamically stable patients, the nature and order of investigations is a matter of debate. The most accepted order is aortic imaging followed by investigation for oesophageal or tracheobronchial tree injury (i.e. contrast study, endoscopy)^[2]. Cornwell *et al.*^[4] challenged this order of investigations in a retrospective study and suggested that delay in intervention for oesophageal injury, due to delay in investigation, is the principal cause of septic complications. Contrast enhanced helical CT scanning is a safe, efficient and cost-effective diagnostic tool. Further organ specific evaluation can be performed on

Abstract

Keywords

Introduction

Case report

Discussion

Learning point

References

Figure 1

Figure 2

Figure 3

Figure 4

Home Page

Title Page

◀ ▶

◀ ▶

Go Back

Full Screen

Close

Quit

GR

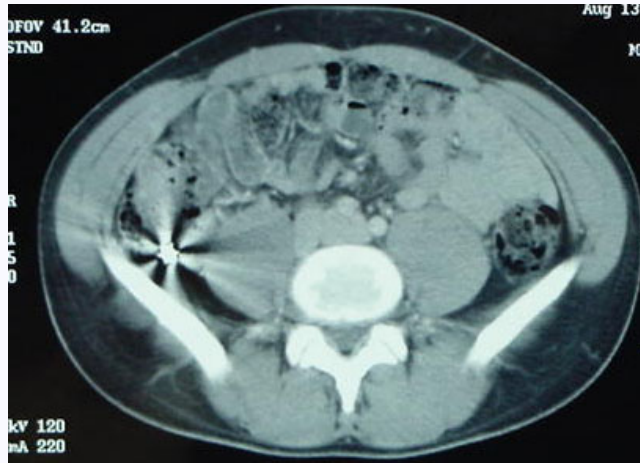


Fig. 4. Bullet in caecal pole on CT abdomen.

the basis of the information provided by the CT scan [1,2,5,6]. If there is no significant finding on the CT scan, patients can be observed safely without further investigations.

Patients with massive bleeding from intercostal drains, or with cardiac tamponade who become unstable during the period of observation or patients with obvious injury demonstrated during the course of investigation go on to surgery. All other patients can be treated conservatively until full recovery [2].

In this particular case it is very difficult to be sure about the exact path of the bullet. There are two possible mechanisms. First, a bullet entered the mediastinum, hit the right side of the lower oesophagus, entered into the lumen, travelled the entire distance of the gastrointestinal tract and came out in the stool. An opening in the lower oesophagus presumably spontaneously sealed off immediately and hence the patient did not develop mediastinitis and remained well. Contusion of the bronchus and/or lung could explain

Abstract

Keywords

Introduction

Case report

Discussion

Learning point

References

Figure 1

Figure 2

Figure 3

Figure 4

Home Page

Title Page

◀ ▶

◀ ▶

Go Back

Full Screen

Close

Quit

GR

the episode of haemoptysis. Spontaneous sealing of an opening in the oesophageal wall, of the size that can admit a bullet, is extremely unlikely and has not been reported before. However, three cases of oesophageal injury followed by transluminal migration of the bullet have been reported. All these three patients needed surgical treatment^[7,8]. Patients with such injuries usually need early intervention to prevent sepsis and probable death^[9]. The second explanation is that the bullet hit the right bronchus, entered the lumen and was coughed up into the nasopharynx from where it was swallowed. Spontaneous endobronchial erosion and expectoration of a retained bullet has been reported before^[10]. Choh and Adler^[11] reported a case where an intrabronchial bullet was removed with a rigid bronchoscope. This patient did not require a thoracotomy.

In summary this patient had a penetrating wound to his thorax, resulting in the bullet traversing his gastrointestinal tract without further injury or intervention. However, the method by which the bullet entered his gut remains a mystery.

Learning point

Low energy transfer rounds can often take surprisingly devious courses through the body and the trauma surgeon must be alert to all possibilities and make no assumptions about the intactness or otherwise of any intrathoracic or intra-abdominal organ until satisfactory screening investigations have been completed. In this respect a spiral CT is a good investigation. A gastroscopy in this case was contraindicated—it would have been a shame if there had been a sealed perforation of the oesophagus and this were disrupted by the instrumentation.

References

1. Stassen NA, Lukan JK, Spain DA *et al.* Reevaluation of diagnostic procedures for transmediastinal gunshot wounds. *J Trauma* 2002; 53: 635–8. [MEDLINE Abstract](#)

[Abstract](#)
[Keywords](#)
[Introduction](#)
[Case report](#)
[Discussion](#)
[Learning point](#)
[References](#)

[Figure 1](#)

[Figure 2](#)

[Figure 3](#)

[Figure 4](#)

[Home Page](#)

[Title Page](#)

◀ ▶

◀ ▶

[Go Back](#)

[Full Screen](#)

[Close](#)

[Quit](#)

GR

2. Degiannis E, Benn CA, Leandros E *et al.* Transmediastinal gunshot injuries. *Surgery* 2000; 128: 54-8. [MEDLINE Abstract](#)
3. Nagy KK, Roberts RR, Smith RF *et al.* Trans-mediastinal gunshot wounds: are “stable” patients really stable? *World J Surg* 2002; 26: 1247-50. [MEDLINE Abstract](#)
4. Cornwell EE III, Kennedy F, Ayad IA *et al.* Transmediastinal gunshot wounds. A reconsideration of the role of aortography. *Arch Surg* 1996; 131: 949-52. [MEDLINE Abstract](#)
5. Hanpeter DE, Demetriades D, Asensio JA *et al.* Helical computed tomographic scan in the evaluation of mediastinal gunshot wounds. *J Trauma* 2000; 49: 689-94. [MEDLINE Abstract](#)
6. Salzano A, De Rosa A, Carbone M *et al.* The role of computed tomography in gunshot lesions of the chest. The authors' personal experience. *Radiol Med (Torino)* 1999; 98: 356-60. [MEDLINE Abstract](#)
7. Hughes JJ. Bullet injury to the esophagus detected by intestinal migration. *J Trauma* 1987; 27: 1362-4. [MEDLINE Abstract](#)
8. Pass LJ, LeNarz LA, Schreiber JT, Estrera AS. Management of esophageal gunshot wounds. *Ann Thorac Surg* 1987; 44: 253-6. [MEDLINE Abstract](#)
9. Naude GP, van Zyl F, Bongard FS. Gunshot injuries of the lower oesophagus. *Injury* 1998; 29: 95-8. [MEDLINE Abstract](#)
10. Saunders MS, Cropp AJ, Awad M. Spontaneous endobronchial erosion and expectoration of a retained intrathoracic bullet: case report. *J Trauma* 1992; 33: 909-11. [MEDLINE Abstract](#)
11. Choh JH, Adler RH. Penetrating bullet wound of chest with bronchoscopic removal of bullet. *J Thorac Cardiovasc Surg* 1981; 82: 150-3. [MEDLINE Abstract](#)

[Abstract](#)[Keywords](#)[Introduction](#)[Case report](#)[Discussion](#)[Learning point](#)[References](#)[Figure 1](#)[Figure 2](#)[Figure 3](#)[Figure 4](#)[Home Page](#)[Title Page](#)[Go Back](#)[Full Screen](#)[Close](#)[Quit](#)