

# An unusual primary pulmonary carcinoma

J. Pickles, D. M. Bailey and C. G. Wathen

*Wycombe Hospital, Queen Alexandra Road, High Wycombe, HP11 2TT, UK*

*Corresponding address: Dr J. Pickles, 5 Grants Mews, 65 Princes St, Oxford OX4 1DF, UK*

Date accepted for publication February 2002

## Abstract

ACC is an unusual pulmonary neoplasm, accounting for 0.09%–0.2% of all lung cancers. It is a low-grade tumour with unusual histological features and rarely metastasises outside the lungs. We describe a case with bilateral renal metastases. We discuss the clinical and histological features, and the implications for its treatment.

## Keywords

Adenoid cystic carcinoma; pulmonary carcinoma; lung cancer.

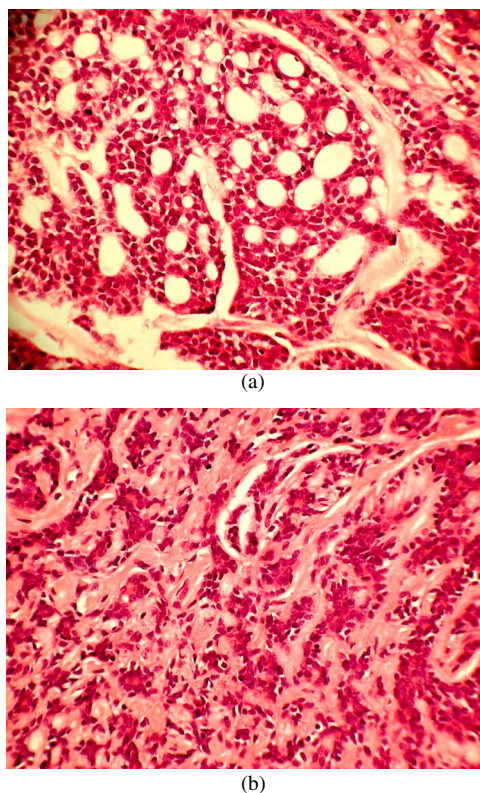
## Case report

In March 1995, a 47-year-old carpenter presented with a three month history of a non-productive cough that was not responding to antibiotic therapy. He had no other respiratory symptoms and his appetite and weight were stable. He was noted to be a smoker of 20 years. On examination there were signs of right basal consolidation. His chest radiograph (CXR) showed a rounded lesion at his right heart border with loss of the bronchus intermedius. Routine haematology and biochemistry was normal. A staging CT scan showed an extensive right hilar mass with distal pneumonia and partial collapse. Lymphadenopathy could not be excluded radiologically because of the extent of the mass. A CT scan of the abdomen was normal. Bronchoscopy confirmed a tumour almost occluding the bronchus intermedius and biopsies showed ACC (Fig. 1).

He was referred for surgical assessment and underwent mediastinoscopy and rigid bronchoscopy. Lymph node biopsy showed reactive changes only and he underwent right middle and lower lobectomies. The surgeons felt the resection margins were macroscopically complete, although histology revealed tumour at the hilar soft tissue margin. Post-operatively, he developed a pneumonia and parapneumonic effusion that responded to antibiotics.

A CT scan at 1 year showed no recurrence. He was reviewed annually with normal CXR for 4 years. In the 5th year, his CXR showed several pulmonary nodules in both lung fields. On examination, his chest was clear but there was a large, mobile, palpable left renal mass. Repeat haematology and biochemistry was normal. Repeat CT scans confirmed multiple pulmonary nodules and a large left mass. The differential diagnosis included metastatic adenoid cystic carcinoma and hypernephroma, hypernephroma with cannon ball metastases and metastatic adenoid cystic carcinoma.

A percutaneous CT guided biopsy of the pulmonary lesions confirmed ACC. A left radical nephrectomy and biopsy of right renal mass was performed. Histology of both kidneys confirmed metastatic ACC. He is still well 4 months after surgery and 10 months after the appearance of metastases.



**Fig. 1.** Adenoid cystic carcinoma. (a) Cribriform pattern; (b) trabecular pattern. Haematoxylin and eosin, magnification  $\times 200$ .

## Discussion

Primary pulmonary ACC is an unusual cause of lung cancer, accounting for 0.09–0.2% of cases and fewer than 100 cases reported in the literature. As it arises in the transbronchial mucosal glands it occurs mainly in the central airways (i.e. the trachea and major bronchi) where these glands predominate. Thus, primary tracheal cancers account for 0.1% of all lung cancers, but 30% of these are ACCs<sup>[1]</sup>. Our case is unusual as it extended peripherally.

In the largest reported series of pulmonary ACC the mean age was 44.8 years (range 15–80 years) with a male: female ratio of 1 : 1.1 and a variety of presentations were noted; breathlessness (72% cases), wheeze (39% cases), cough (23% cases), stridor (21% cases), haemoptysis (18% cases) and hoarseness due to vocal cord palsy<sup>[2]</sup>. Tracheal tumours are often diagnosed late because of non-specific symptoms and absence of CXR changes (mean 15 months)<sup>[2]</sup>.

Primary pulmonary ACC has a unique histology showing submucosal and perineural infiltration and often extends 1cm or more beyond macroscopic margins. It is therefore commonly mistaken to be completely resected at the time of surgery (as in our case). There are three histological subtypes; cribriform/cylindromatous is the most frequent, tubular, and solid, which is associated with an aggressive clinical course and distant metastases. It is a slow growing low-grade malignancy that metastasizes within the lungs. The histopathological features are distinctive enough to allow diagnosis on standard haematoxylin-eosin-stained section (Fig. 1). Occasionally, with small biopsies, immunohistochemistry is required to distinguish ACC from adenocarcinoma (keratin, actin, and vimentin stain positively in ACC)<sup>[3]</sup>. Metastases outside the lungs are rare and occur late (in one series 12–300 months, mean 100 months) and have been reported to occur up to 3 decades after the original tumour<sup>[1, 2, 3]</sup>. The commonest sites for these distal metastases are the liver, bone and brain<sup>[2]</sup>. Renal metastases are unusual, being reported in only one other case<sup>[2]</sup>.

Optimal management is surgical resection with a reported survival rate of 65–80% at 5 years and 50–60% at 10 years despite frequent incomplete resection margins which relate to its unpredictable pattern of extension<sup>[2, 3]</sup>. One series demonstrated no significant difference in survival data between those with incomplete resection, mean survival 7.5 years (range 4 months to 21 years) and those with complete resection, mean survival 9.8 years (range 1–29 years), although the patient numbers are small<sup>[2]</sup>. This compares with a significant mortality rate if total pneumonectomy is performed, especially in patients aged over 70. Therefore, although surgery is associated with the best survival

rates, reducing rather than ensuring complete resection margins, which is associated with a higher post-operative complication rate, should be the aim<sup>[3]</sup>. Adjuvant radiotherapy pre-operatively or post-operatively is felt to reduce local recurrence but no statistically significant difference in survival has been shown<sup>[2]</sup>.

In those with extensive inoperable disease, primary radiotherapy can achieve good survival results, with a mean survival in one study of 6.2 years (range 2 months to 14.3 years)<sup>[2]</sup>. The majority of cases treated with primary radiotherapy alone later die from local recurrence. Palliative therapy of tracheal tumours can be achieved by a combination of laser photoresection, endobronchial and transthoracic radiotherapy, even with poor lung function, and achieve reasonable survival<sup>[5, 6]</sup>. The optimum treatment for metastatic disease is unclear and although survival is shortened it is significantly greater than for other types of lung cancers<sup>[1, 2, 3, 4]</sup>.

In summary, we have described an unusual presentation of ACC with bilateral renal metastases and loco-regional recurrence. The unique histological characteristics and clinical course of this tumour means it is doubtful if a complete cure can ever be achieved and so life-long follow ups are recommended<sup>[3]</sup>.

## Acknowledgements

Photographs taken from slides supplied by Dr Margaret Burke, Royal Brompton and Harefield NHS Trust. No funding.

## References

1. Kawashima O, Hirai T, Kamiyoshihara M *et al.* Primary adenoid cystic carcinoma in the lung: report of two cases and therapeutic considerations. *Lung Cancer* 1998; 211-7.
2. Maziak DE, Todd TRJ, Keshavjee SH *et al.* Adenoid cystic carcinoma of the airway: thirty two year experience. *J Thorac Cardiovasc Surg* 1996; 112: 1522-32.
3. Moran CA. Primary salivary gland-type tumors of the lung. *Semin Diagn Pathol* 1995; 12: 106-22.
4. Prommegger R, Salzer GM. Long-term results of surgery for adenoid cystic carcinoma of the trachea and bronchi. *Euro J Surg Onc* 1998; 24: 440-4.
5. Aggarwal A, Tewari S, Mehta AC. Successful management of adenoid cystic carcinoma of the trachea by laser and irradiation. *Chest* 1999; 116: 269.
6. Boedker HA, Kristensen D. A method for selective endobronchial and endotracheal irradiation. *J Thorac Cardiovasc Surg* 1982; 84: 59-61.