

# Hernia ovary inguinale with ovulating luteal cyst: a case report

Y. Koak and E. J. Chaloner

*Department of General Surgery, Whittington Hospital, Highgate, London, UK*

*Corresponding address: Mr E Chaloner, Consultant Surgeon, Academic Vascular Surgical Unit, Middlesex Hospital, Mortimer Street, London, W1N 8AA, UK.*

*E-mail: eddie.chaloner@diversity.net*

Date accepted for publication February 2002

## Abstract

The inguinal hernia sac can occasionally contain unusual intra and extra peritoneal structures. A case of acute presentation of ovulating ovary in indirect inguinal hernia is presented. This has not been described previously.

## Keywords

Fallopian tubes abnormalities; fallopian tubes surgery; hernia; inguinal surgery; ovary surgery.

## Case report

A 10-year-old ovulating Afro-Caribbean female was presented after 48 h of acute pain in the left groin and an enlarging tender lump in left inguinal area. She described the pain as similar to period pains. There was no associated fever, nausea, vomiting, abdominal pain or vaginal discharge present. She was born prematurely at 32 weeks and had bilateral inguinal herniae and umbilical hernia repairs performed at the age of 3 months. She had begun menstruating 9 months before presentation.

On examination the patient was afebrile, normotensive and had developing secondary sexual characteristics. There was no lymphadenopathy present. Abdominal examination was unremarkable. In the left groin a tender immobile lump, 4 cm in diameter, was palpated. There was no cough impulse elicited.

Urinalysis was normal. Urinary beta-hcg was negative. Blood investigations of full blood count, urea and electrolytes were normal. She was sickle-negative. Ultrasound scan showed a  $4.1 \times 2.8 \times 4 \text{ cm}^3$  ovoid cystic mass in left inguinal region which had the bowel lying over the top. The lump was superficial and medial to femoral vessels.

Surgical exploration was performed through an inguinal incision and revealed a cystic mass lying in an indirect inguinal hernia (Fig. 1). The mass was attached to the fallopian tube. The appearance of the mass was suggestive of ovulating cystic ovary. A biopsy was taken and the cyst ruptured. The hernia was reduced and defect closed. Post-operative recovery was unremarkable and the patient was well at 3 months' follow up. The histological examination confirmed ovarian tissue with stroma containing follicles at various stages of development. There was no evidence of malignant change noted.

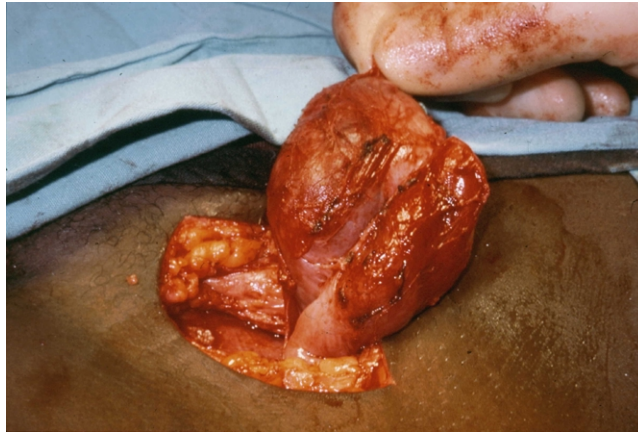


Fig. 1. Ovary in the inguinal canal.

## Discussion

Anomalous presence of fully developed female reproductive organs in the inguinal canal is extremely rare, with less than 5 cases reported<sup>[1, 2]</sup>. Occurrence of an ovary in an inguinal hernia in adult females is a common indicator of genital tract development defects<sup>[1]</sup>. Even though our ovulating patient had had a congenital inguinal hernia and was born prematurely, there was no development defect. In fact, this patient had a precocious puberty and represents the first reported case of an ovulating ovary in a recurrent inguinal hernia.

Occurrence of ovary and fallopian tubes in inguinal herniae has been noted in several case reports in premature infants and this is related to defects in genital tract, ovarian agenesis, Mullerian dysgenesis and ambiguous genitalia<sup>[2, 3, 4]</sup>. The lateral fusion defects associated with Mullerian ductal development can also lead to the rare congenital anomaly hernia uterus inguinale, a condition in which endometrium and myometrium are found in an ectopic location in the inguinal canal<sup>[5]</sup>. In our case there was no such secondary sexual development defect noted. It is also suggested that the round ligament imitates testicular descent<sup>[6]</sup>. However, the rarity of inguinal ovary and fallopian tube as compared to prevalence of non-existent or delayed testicular descent argues against any such imitation.

The nature and location of gonads in inguinal hernia can be determined by using high resolution real-time ultrasound scans<sup>[7, 8]</sup>. It is claimed that the appearance of an ovary is quite distinct from solid homogeneous testis<sup>[7]</sup>. However, in our patient an indeterminate cystic mass was visualised and the exact relationship to the inguinal canal was difficult to determine. Though, some cases have been managed conservatively early, recognition and reduction of an ovary is thought to be important to decrease the risk of infarction<sup>[4, 9]</sup>. The presence of an ovary in the inguinal canal requires laparoscopic or conventional surgical exploration<sup>[10, 11]</sup>. The aim of operative management of this rare anomaly is to preserve and reposition the ovary in the abdominal cavity<sup>[11]</sup>.

## References

1. Bradshaw KD, Carr BR. Ovarian and tubal inguinal hernia. *Obstet Gynecol* 1986; 68: 50S.
2. Amarin ZO, Hart DM. Inguinal ovary and fallopian tube-an unusual hernia. *Int J Gynecol Obstet* 1988; 27: 141.
3. Gnidec AA, Marshall DG. Incarcerated direct inguinal hernia containing uterus, both ovaries, and fallopian tubes. *J Pediatr Surg* 1986; 21: 986.
4. Oudesluys-Murphy AM, Teng HT, Boxma H. Spontaneous regression of clinical inguinal hernias in preterm female infants. *J Pediatr Surg* 2000; 35: 1220.
5. Elliott DC, Beam TE, Denapoli TS. Hernia uterus inguinale associated with unicornuate uterus. *Arch Surg* 1989; 124: 872.
6. Ozbey H, Ratschek M, Schimpl G, Hollwarth ME. Ovary in hernia sac: prolapsed or a descended gonad? *J Pediatr Surg* 1999; 34: 977.
7. Goske MJ, Emmens RW, Rabinowitz R. Inguinal ovaries in children demonstrated by high resolution real-time ultrasound. *Radiology* 1984; 151: 635.

8. George EK, Oudesluys-Murphy AM, Madern GC, Cleyndert P, Blomjous JG. Inguinal hernias containing the uterus, fallopian tube, and ovary in premature female infants. *J Pediatr* 2000; 136: 696.
9. Munden M, McEniff N, Mulvihill D. Sonographic investigation of female infants with inguinal masses. *Clin Radiol* 1995; 50: 696.
10. Vaughn TC, Jones HL. Laparoscopic repair of bilateral inguinal hernias in a patient with mullerian agenesis. *Fertil Steril* 2000; 73: 1238.
11. Kriplani A, Banerjee N, Aminni AC, Kucheria K, Takkar D. Hernia uterus inguinale in a 46, XX female. A case report. *J Reprod Med* 2000; 45: 48.