

# Growing adrenal mass misdiagnosed as the cause of hirsutism in a patient with an ovarian Leydig cell tumor

Maria H. P. Dietvorst<sup>a</sup>, Suzanne Poots<sup>b</sup> and Peter van Wijngaarden<sup>a</sup>

<sup>a</sup>*Department of Internal Medicine, Amphia Hospital, Breda, The Netherlands; and*

<sup>b</sup>*Department of Gynecology and Obstetrics, Amphia Hospital, Breda, The Netherlands*

*Corresponding address: P. van Wijngaarden, Department of Internal Medicine, Amphia Hospital, PO Box 90158, 4800 RK Breda, The Netherlands.*

*E-mail: pvanwijngaarden@amphia.nl*

Date accepted for publication 22 September 2009

## Abstract

A case is described involving a 71-year-old hirsute woman with a growing adrenal tumor and a high serum testosterone level, which did not normalize after adrenalectomy. Following this she was found to have a testosterone-producing ovarian Leydig cell tumor. This case provides key features that can help distinguish adrenal and ovarian causes of hirsutism.

## Keywords

Androgen-producing tumor; hirsutism; Leydig cell tumor.

## Introduction

Hirsutism is defined as excessive, androgen-dependent terminal hair growth that appears in a male-like pattern in women<sup>[1]</sup>. Around 5–10% of women of reproductive age are hirsute. The most common cause of androgen excess in women is polycystic ovary syndrome (PCOS)<sup>[2]</sup>. Only in a minority of cases is hirsutism caused by an androgen-secreting ovarian or adrenal tumor<sup>[3]</sup>. Diagnostic evaluation of a hirsute patient should be concentrated on the exclusion of a serious underlying disease.

## Case report

In October, 2006, a 71-year-old woman was referred to our department because of an elevated hemoglobin level. The patient had a 2-month history of general malaise and a 5-kg weight loss. She had a past medical history of hypertension, total hip replacements and hysterectomy. Her medication included aspirin, amlodipine and metoprolol.

On examination, the patient had generalized hirsutism and androgenic alopecia. There were no signs of Cushing syndrome. On direct questioning, the patient reported a recent development and rapid progression of male pattern hair growth and temporal balding. She had no features of virilization, except for deepening of her voice.

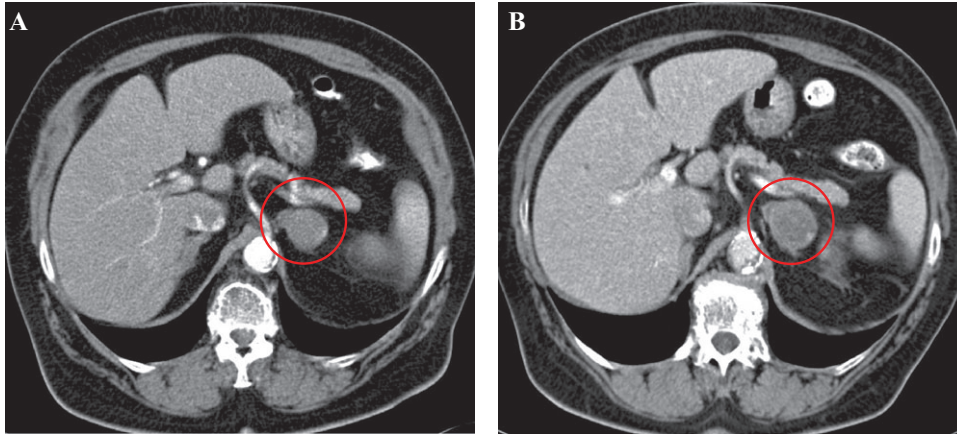


Fig. 1. Abdominal CT scans showing growth of the left adrenal mass.

Blood tests showed an elevated hemoglobin level (11.3 mmol/L, normal 7.5–10 mmol/L) and an inappropriately high erythropoietin (EPO) value (29 U/L, normal 8–34 U/L). Total testosterone concentration was also elevated (16.1 nmol/L, normal 0.8–2.8 nmol/L).

Computed tomography (CT) of the abdomen revealed a right renal tumor measuring 4 × 4 cm and a 3.4 cm left adrenal mass. The patient underwent right radical nephrectomy. Histopathologic examination showed a papillary renal cell carcinoma not invading the fibrous capsule.

After a few months of delay due to a total hip revision, we saw the patient again. Hemoglobin level had been normalized. Because of the high total testosterone and the adrenal mass, we performed some additional laboratory tests. Measurement of dehydroepiandrosterone-sulfate (DHEA-S), aldosterone, renin, catecholamines in 24-h urine and a dexamethasone suppression test, revealed normal results. A second abdominal CT scan showed growth of the left adrenal mass from 3.4 to 4.2 cm (Fig. 1). The patient underwent a left adrenalectomy. Histopathologic analysis revealed a well-circumscribed hemorrhagic tumor without signs of malignancy.

Unfortunately, her total testosterone level remained high postoperatively. Although both CT scans showed normal ovaries, we decided to refer our patient to a gynecologist. Transvaginal ultrasound identified a small solid mass (1.5 × 2 cm) in the right ovary, which was confirmed by a third abdominal CT scan. The patient underwent an oophorectomy. Histopathologic examination revealed a totally removed Leydig cell tumor. When last seen, in November, 2008, the patient was well and total testosterone concentration had been normalized. Her male pattern hair growth had disappeared.

## Discussion

The prevalence of androgen-secreting neoplasms in woman with androgen excess is about 0.2%<sup>[3]</sup>. Ovarian tumors associated with hyperandrogenism predominantly belong to the group of sex cord-stromal tumors. Pure Leydig cell tumors of the ovary constitute a very rare, often benign cause of hirsutism<sup>[4]</sup>.

Recent or rapid development of hirsutism, onset in later life and symptoms of virilization, suggest the presence of an androgen-producing neoplasm<sup>[1]</sup>. Normally, adrenal glands and ovaries contribute about equally to testosterone production in women. Very high values of total testosterone (>6.94 nmol/L) heighten the likelihood of an underlying adrenal or ovarian tumor<sup>[1]</sup>. Markedly elevated levels of testosterone are also seen in ovarian hyperthecosis<sup>[5]</sup>.

DHEA-S is a marker of adrenal androgen production. A high concentration of total testosterone in combination with an elevated DHEA-S value (>19 μmol/L) is very suggestive of an adrenal androgen-secreting tumor<sup>[1]</sup>. Moreover, most adrenal tumors are carcinomas that often secrete not only androgen but also cortisol<sup>[6]</sup>. Therefore the patient usually also has symptoms and signs of Cushing syndrome.

Some adrenal tumors may lose the ability to sulfate DHEA. Therefore, a normal DHEA-S value does not exclude an androgen-producing adrenal neoplasm<sup>[6]</sup>. In our patient, serum DHEA-S level was normal. However, consecutive CT scans showed a growing adrenal mass and a normal aspect of both ovaries. Based on these findings, we concluded that the adrenal tumor most probably caused the androgen excess in our patient. Because of the measurements of the growing

adrenal mass (>4 cm), we decided to perform an adrenalectomy. Unfortunately, the total testosterone level remained high postoperatively.

In retrospect, the clinical and laboratory findings in our patient indicated an ovarian source of androgen excess.

### Teaching points

- Adrenal and ovarian androgen-secreting tumors are rare but serious causes of hirsutism.
- Recent or rapid development of hirsutism, onset in later life and symptoms of virilization, should raise suspicion for an androgen-producing neoplasm.
- Normally, adrenal glands and ovaries contribute about equally to testosterone production in women.
- Very high levels of total testosterone indicate the presence of ovarian hyperthecosis, an ovarian tumor, or an adrenal tumor.
- Most adrenal tumors are carcinomas that often secrete not only androgen but also cortisol.
- Elevated DHEA-S is a marker of increased adrenal androgen production.
- Transvaginal ultrasound scan is a cheap and sensitive (92%) tool in the diagnosis of ovarian lesions<sup>[7]</sup>.

### References

1. Rosenfield RL. Hirsutism. *N Engl J Med* 2005; 353: 2578–88. doi:10.1056/NEJMcp033496. PMID:16354894.
2. Azziz R. The evaluation and management of hirsutism. *Obstet Gynecol* 2003; 101: 995–1007. doi:10.1016/S0029-7844(02)02725-4. PMID:12738163.
3. Azziz R, Sanchez LA, Knochenhauer ES, et al. Androgen excess in women: experience with over 1000 consecutive patients. *J Clin Endocrinol Metab* 2004; 89: 453–62. doi:10.1210/jc.2003-031122.
4. Sanz OA, Martinez PR, Guarch RT, et al. Bilateral Leydig cell tumour of the ovary: a rare cause of virilization in postmenopausal patient. *Maturitas* 2007; 57: 214–6. doi:10.1016/j.maturitas.2006.11.013. PMID:17289310.
5. van Heyningen C, MacFarlane IA, Driver MJ, et al. Virilization due to ovarian hyperthecosis in a postmenopausal woman. *Gynecol Endocrinol* 1988; 2: 331–8. doi:10.3109/09513598809107656. PMID:3232554.
6. Derksen J, Nagesser SK, Meinders AE, et al. Identification of virilizing adrenal tumors in hirsute women. *N Engl J Med* 1994; 331: 968–73. doi:10.1056/NEJM199410133311502. PMID:8084355.
7. Rieber A, Nüssle K, Stöhr I, et al. Preoperative diagnosis of ovarian tumors with MR imaging: comparison with transvaginal sonography, positron emission tomography, and histologic findings. *AJR Am J Roentgenol* 2001; 177: 123–9.