

Accessory cystic duct identification in laparoscopic cholecystectomy

U. Parampalli, S. Helme, G. Asal and P. Sinha

Department of General Surgery, Princess Royal University Hospital, Orpington, Kent, BR6 8ND, UK

Corresponding address: Mr Prakash Sinha, Consultant, Department of General Surgery Princess Royal University Hospital, Orpington, Kent, BR6 8ND, UK.

E-mail: p.sinha@btinternet.com

Date accepted for publication 8 September 2008

Abstract

We report the case of a 53-year-old lady who underwent laparoscopic cholecystectomy and was found to have an accessory cystic duct close to the fundus. Careful dissection of the liver bed was done and the duct clipped preventing a bile leak. The presence of such ducts though rare should be identified during surgery to prevent potential complications.

Keywords

Accessory cystic duct; laparoscopic cholecystectomy.

Case report

A 53-year-old lady presented with symptoms suggestive of acute pancreatitis. Investigations confirmed the same and it was found to be gall stone related. She was managed conservatively until her symptoms subsided and biochemical parameters returned to normal.

An abdominal ultrasound scan revealed multiple stones within the gallbladder and common bile duct (CBD) measuring 8 mm in diameter. Magnetic resonance cholangiopancreatography (MRCP) showed multiple stones in the gallbladder, common bile duct measuring 7.3 mm with the possibility of tiny non-obstructing calculi at the distal end. Radiological investigations did not reveal any anatomical abnormalities. Following this she was discharged.

She returned for an interval laparoscopic cholecystectomy. At surgery normal anatomy was identified in the Calot's triangle. The cystic duct and artery were isolated, double clipped and divided. On careful dissection of the gallbladder from the liver bed, a tubular structure was found running from the liver bed to the body of the gallbladder close to the fundus. The tubular structure was clipped close to the liver bed and the gall bladder end was divided. Bile was seen leaking from the gall bladder end confirming this was an accessory cystic duct (Fig. 1). The rest of the dissection was uneventful and the gallbladder was removed safely. She made a good recovery and was later discharged.

Discussion

Ten percent of biliary collecting systems have variations in anatomy as a result of their complex embryological development^[1]. Ninety percent of bile duct anomalies are found close to

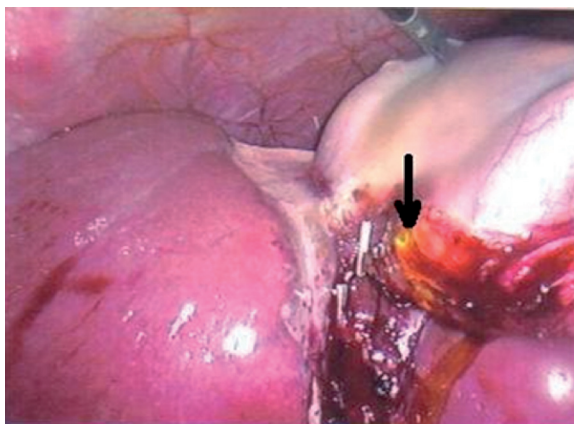


Fig. 1. Accessory cystic duct.

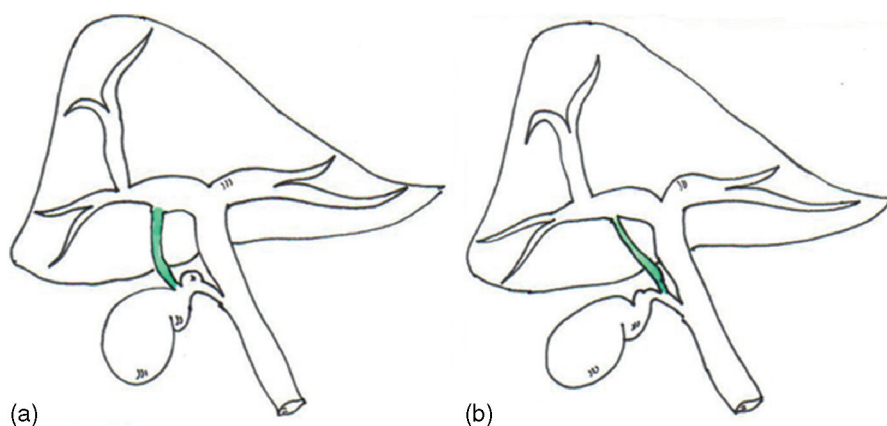


Fig. 2. (a) Duct of Luschka; (b) Cystohepatic duct.

Calot's triangle. Failure to identify these may result in bile leak. This causes significant morbidity and has been reported to occur in 0.2-2% of cases after laparoscopic cholecystectomy^[2].

Accessory bile ducts in the gallbladder fossa have been classified into two types: the bile duct of Luschka and the cystohepatic duct. The bile duct of Luschka (subvesical duct) is a slender duct 1-2 mm in diameter which runs in the submucosa of the posterior gall bladder wall. It drains subsegmental areas of the liver into the right hepatic duct (Fig. 2). Its prevalence has been estimated at one-third of the population^[3].

The cystohepatic duct drains the subsegmental parenchymal distribution of the right lobe of the liver to the right hepatic duct or the cystic duct (Fig. 2). Its prevalence has been estimated at 1-2% of surgical cases.

Double cystic ducts are also classified into, 'Y' type where both ducts meet and form a single duct, 'H' type where an accessory duct joins the right, left or common hepatic duct, and the trabecular type in which the accessory duct directly enters the liver substance^[4].

Preoperative identification of such anomalies can be difficult but helps in planning surgery and avoiding duct damage or bile leaks. Studies report that magnetic resonance cholangiography has 66% sensitivity to show accessory bile ducts, whereas helical computed tomography (CT) cholangiography has up to 100% sensitivity^[5]. Routine use of intra-operative cholangiography is emphasized but not practiced widely. In the above case, the accessory duct was identified close to the fundus only after meticulous dissection of the liver bed.

Management of bile leaks

Seventy-five percent of bile leaks are classified as major injuries occurring from common bile ducts, biliary confluence and hepatic ducts. Primary end to end repair over T-tube, direct closure and Roux-en-Y hepaticojejunostomies are used for the treatment of major injuries^[6]. 24.3% of bile

leaks occur from cystic ducts and ducts of Luschka. Sclerotherapy and embolization have been tried but surgery is the treatment of choice.

Teaching point

Routine investigations for gall stone disease do not detect all cases with variable anatomy. As in our case, MRCP did not reveal the accessory duct. Accessory ducts are common in the triangle of Calot^[7] but less than 10% are found near the body or fundus. A scrupulous dissection beyond the Calot's triangle should be carried out during laparoscopic cholecystectomy to avoid the potential complication of bile leak.

References

1. Senapathi A, Wolfe JH. Accessory cystic duct - an operative hazard. *J R Soc Med* 1984; 77: 845-6.
2. Spanos CP, Syrakos T. Bile leaks from the duct of Luschka (subvesical duct): a review. *Langenbeck's Arch Surg* 2006; 391: 441-7.
3. Aoki T, Imamura H, Sakamoto Y, *et al.* Bile duct of Luschka connecting with the cystohepatic duct: the importance of cholangiography during surgery. *Am J Roentgenol* 2003; 180: 694-6.
4. Huston TL, Dakin GF. Double cystic duct. *Can J Surg* 2008; 51: E9-10.
5. Hirao K, Miyazaki A, Fujimoto T, Isomoto I, Hayashi K. Evaluation of aberrant bile ducts before laparoscopic cholecystectomy: helical CT cholangiography versus MR cholangiography. *Am J Roentgenol* 2000; 175: 713-20.
6. Stewart L, Way LW. Bile duct injuries during laparoscopic cholecystectomy. Factors that influence the results of treatment. *Arch Surg* 1995; 130: 1123-8.
7. Schwartz SI. Gall bladder and extrahepatic biliary system. In: Schwartz SI, Shires GT, Spencer FC, editors. *Principles of surgery*. 6th ed. New York: McGraw-Hill; p. 1367-9.