

# A case of haemoptysis diagnosed using digital video endoscopy and treated with the holmium-YAG laser

H. M. Al-Reefy, A. M. Balfour and M. G. Dilkes

*Department of ENT Surgery, St Bartholomew's Hospital, West Smithfield, London, EC1A 7BE, UK*

Date accepted for publication 31 July 2006

## Abstract

We report a case of persistent haemoptysis, initially investigated by chest physicians. An Ear, Nose and Throat (ENT) opinion was sought because no source for the bleeding could be found. On video-endoscopic examination of the trachea using a three chip digital camera system, a vascular lesion, possibly an arteriovenous malformation, was seen on the anterior tracheal wall. This was successfully coagulated using the holmium-YAG laser, with resultant cessation of bleeding.

**Abstract**

Keywords

Case report

Discussion

Teaching point

Conclusion

References

Figure 1

Figure 2

Home Page

Title Page

◀◀ ▶▶

◀ ▶

Go Back

Full Screen

Close

Quit

# GR

## Keywords

Haemoptysis; video-endoscopy; holmium-YAG; laser.

## Case report

An 81-year-old man was referred for an ENT opinion by the chest physicians. He had originally been referred to them with persistent haemoptysis of unknown origin. A computed tomography (CT) scan of the chest and flexible bronchoscopy had failed to identify the source of the bleeding. When seen in the ENT clinic, the patient was able to cough up bright red blood in his sputum. The blood was not mixed in, rather it was on the surface of the sputum, suggesting a source in the upper airway. Full ENT examination, including flexible direct laryngoscopy, was unremarkable. The patient was reassured and discharged. Several weeks later he returned, increasingly concerned regarding the haemoptysis. In view of the concern and the lack of a diagnosis, it was decided to perform an examination under general anaesthesia, using rigid video-endoscopy with a Storz 0 degree rigid bronchoscopy telescope, linked to a Storz three chip digital camera system.

The patient was placed supine on the operating table, and a suspension laryngoscope was placed into the laryngeal introitus. Ventilation was achieved by using an Accutronic Mistral high-frequency jet ventilator and an Accutronic laser safe jet catheter. On inspection of the trachea and main bronchi, a small bleeding point, possibly an arteriovenous malformation, could be seen clearly on the anterior tracheal wall (Fig. 1). No further source of bleeding could be found. A 550  $\mu\text{m}$  laser fibre was passed through a long steel suction catheter for aiming purposes, and attached to the holmium-YAG laser. Using energy levels of 1 J/pulse, and 5 pulses/s, the bleeding area was successfully coagulated in near contact mode until the lesion had disappeared (see Fig. 2). The patient recovered and was discharged home later in the day. There was immediate relief of the haemoptysis, and longer-term follow-up (4 weeks) confirmed the absence of recurrent haemoptysis, implying

[Abstract](#)

[Keywords](#)

[Case report](#)

[Discussion](#)

[Teaching point](#)

[Conclusion](#)

[References](#)

[Figure 1](#)

[Figure 2](#)

[Home Page](#)

[Title Page](#)

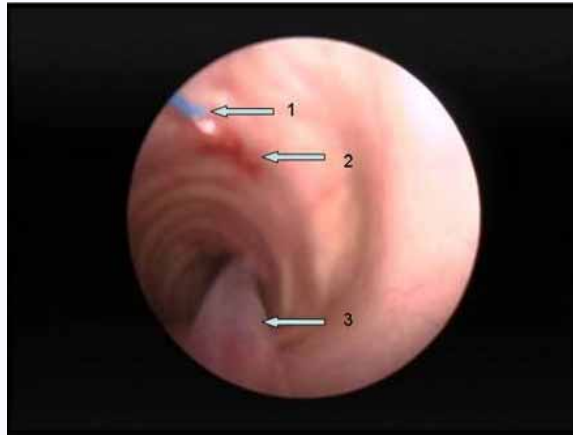


[Go Back](#)

[Full Screen](#)

[Close](#)

[Quit](#)



**Fig. 1.** Upper trachea. Arrow 1 shows the 550  $\mu\text{m}$  holmium-YAG laser fibre in position. Arrow 2 shows the vascular lesion. Arrow 3 points to the jet catheter.

that the bleeding point seen was the cause of the problem, and that it had been successfully treated by laser coagulation.

## Discussion

Haemoptysis is potentially serious, as it is often the first presenting sign of malignant bronchial neoplasia<sup>[1]</sup>. Often, however, the source of the bleeding cannot be found, and this is called idiopathic haemoptysis<sup>[1,2]</sup>. Routine tests include contrast enhanced computerised tomography of the thorax, and flexible bronchoscopy<sup>[3]</sup>.

In this case, these tests did not reveal the source of the bleeding. However, using a digital three chip high-resolution colour video camera, linked to a 0 degree rigid telescopic

[Abstract](#)

[Keywords](#)

[Case report](#)

[Discussion](#)

[Teaching point](#)

[Conclusion](#)

[References](#)

[Figure 1](#)

[Figure 2](#)

[Home Page](#)

[Title Page](#)

[◀◀](#) [▶▶](#)

[◀](#) [▶](#)

[Go Back](#)

[Full Screen](#)

[Close](#)

[Quit](#)

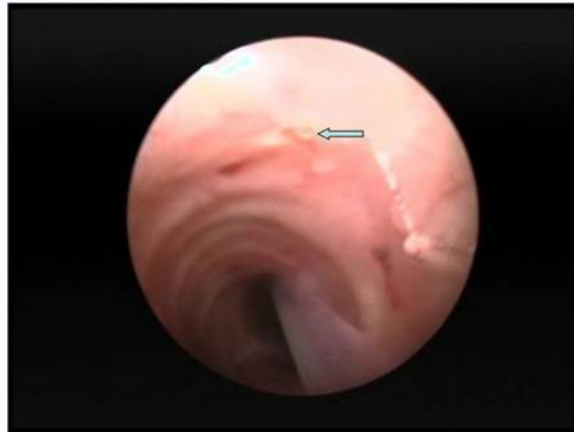

Fig. 2. Upper trachea. The arrow points to the coagulated vascular lesion.

bronchoscope, under general anaesthesia, the bleeding point was clearly seen, thanks to the very clear magnified images available.

Arteriovenous malformations of the upper airway are a rare but recognised cause of haemoptysis<sup>[1]</sup>. They are often associated with hereditary haemorrhagic telangiectasia. They can be treated with laser coagulation using the neodymium-YAG laser<sup>[4]</sup>, sclerotherapy, contact unipolar diathermy, or surgical extirpation, depending on their size. In this case, the holmium-YAG laser was used since it has the advantages of Nd-YAG lasers, i.e. it will transmit down a flexible laser fibre, but is significantly less penetrative through tissue, reducing the risk of immediate or delayed rupture of the tracheal wall, a rare but serious complication of Nd-YAG laser treatment. Because light at this wavelength (2100 nm) penetrates less through tissue than the Nd-YAG laser (1064 nm), it is also better for vaporising and removing tissue. This is because the laser energy is more confined, hence higher, vaporising temperatures are more easily achieved. Furthermore, because of the

[Abstract](#)

[Keywords](#)

[Case report](#)

[Discussion](#)

[Teaching point](#)

[Conclusion](#)

[References](#)

[Figure 1](#)

[Figure 2](#)

[Home Page](#)

[Title Page](#)

[◀◀](#) [▶▶](#)

[◀](#) [▶](#)

[Go Back](#)

[Full Screen](#)

[Close](#)

[Quit](#)

GR

pulsed effect of the light, no laser fibre tip cooling is required, since carbonised particles on the tip are immediately cleared by the high-energy pulse effect. This further reduces the risk of Nd-YAG lasers since air cooling of laser fibre tips has been associated with air embolus.

The holmium-YAG laser is used widely in surgery, most commonly by urologists treating renal tract calculi<sup>[5]</sup>. Its role in ENT surgery is confined to the excision of oropharyngeal cancer and to flexibly destroy less accessible lesions of the airway<sup>[6]</sup>.

## Teaching point

The use of digital video cameras and rigid optical systems allows a very clear view of tracheo-bronchial mucosal disease. The holmium-YAG laser is effective in coagulating small mucosal lesions of the upper airway and may also be useful for the removal of obstructing tumours due to the benefits of using light at this wavelength.

## Conclusion

This case demonstrates that diagnosis of the bleeding point can be achieved using video-endoscopic techniques, and treatment can be safely carried out using the holmium-YAG laser in cases of intractable haemoptysis.

## References

1. Reisz G, Stevens D, Boutwell C, Nair V. The causes of hemoptysis revisited. A review of the etiologies of hemoptysis between 1986 and 1995. *Mo Med* 1997; 94: 633-5. [MEDLINE Abstract](#)
2. Herth F, Ernst A, Becker HD. Long-term outcome and lung cancer incidence in patients with hemoptysis of unknown origin. *Chest* 2001; 120: 1592-4. [MEDLINE Abstract](#)

*Abstract*

*Keywords*

*Case report*

*Discussion*

*Teaching point*

*Conclusion*

*References*

[Figure 1](#)

[Figure 2](#)

[Home Page](#)

[Title Page](#)

◀▶

◀▶

[Go Back](#)

[Full Screen](#)

[Close](#)

[Quit](#)

**GR**

3. Jean-Baptiste E. Clinical assessment and management of massive hemoptysis. Crit Care Med 2000; 28: 1642-7. [MEDLINE Abstract](#)
4. Shapshay SM, Oliver P. Treatment of hereditary hemorrhagic telangiectasia by Nd-YAG laser photocoagulation. Laryngoscope 1984; 94 (Pt 1): 1554-6.
5. Grasso M. Experience with the holmium laser as an endoscopic lithotrite. Urology 1996; 48: 199-206. [MEDLINE Abstract](#)
6. Sipila J, Scheinin H, Grenman R. Laser bronchoscopy in palliative treatment of malignant obstructing endobronchial tumors. ORL J Otorhinolaryngol Relat Spec 1998; 60: 42-7. [MEDLINE Abstract](#)

[Abstract](#)[Keywords](#)[Case report](#)[Discussion](#)[Teaching point](#)[Conclusion](#)[References](#)[Figure 1](#)[Figure 2](#)[Home Page](#)[Title Page](#)[Go Back](#)[Full Screen](#)[Close](#)[Quit](#)