

Pseudoaneurysm of the superficial temporal artery: case report and review of the literature

J. Shalhoub[†], M. Hamish[‡], M. B. Sikkels[§] and A. H. Davies[‡]

[†]*Department of Accident and Emergency Medicine, Charing Cross Hospital, Fulham Palace Road, London W6 8RF, UK*

[‡]*West of London Vascular Service, Charing Cross Hospital, Fulham Palace Road, London W6 8RF, UK*

[§]*Department of Accident and Emergency Medicine, St Mary's Hospital, Praed Street, London W1 1NY, UK*

Date accepted for publication 8 April 2006

Abstract

Since the first description by Bartholin in 1740, 386 cases of aneurysms of the facial vasculature have been reported in the world literature. Of these, less than 200 were of the superficial temporal artery (STA)^[1]. Such STA lesions are commonly pseudoaneurysms presenting within weeks of direct trauma. We present a case of STA pseudoaneurysm following a closed head injury.

Abstract

Keywords

Case report

Diagnosis

Discussion

Teaching point

References

Figure 1

Figure 2

Home Page

Title Page



Go Back

Full Screen

Close

Quit

GR

Keywords

Pseudoaneurysm; superficial temporal artery; facial vasculature; head trauma.

Case report

An 18-year-old male patient was admitted to the accident and emergency department following an alleged assault during which he experienced a head injury, including direct blunt trauma to the left temporal region. On initial examination, unilateral peri-orbital ecchymosis was evident with a superficial abrasion of the left temporal region. A skull radiograph revealed a fracture of the left zygomatic arch, which was managed conservatively. One month later, he noticed a solitary, painless and slowly enlarging swelling overlying the left parietal bone. A well defined, pulsatile, non-tender mass, measuring 20 mm in the long axis and 10 mm in the short axis could be felt. The pulsatility of the swelling was diminished with pressure applied over the proximal superficial temporal artery (STA). Duplex ultrasonography demonstrated a pseudoaneurysm arising from the anterior branch of the left STA (Fig. 1). The afferent and efferent vessel velocities (systole/diastole) were 70/13 cm/s and 102/37 cm/s, respectively.

In view of the risk of expansion and potential rupture, as well as for cosmetic reasons, the patient was scheduled for surgical excision of the pseudoaneurysm under general anaesthesia. The aneurysm was exposed surgically, proximal and distal arteries ligated (Fig. 2), and the aneurysm removed intact. The procedure was completed without complication, a good cosmetic outcome achieved, and the patient was discharged on the first postoperative day. At 15 months, there is no evidence of recurrence, with the patient remaining asymptomatic.

Diagnosis

Pseudoaneurysm of the superficial temporal artery.

Abstract

Keywords

Case report

Diagnosis

Discussion

Teaching point

References

Figure 1

Figure 2

[Home Page](#)

[Title Page](#)

◀▶

◀▶

[Go Back](#)

[Full Screen](#)

[Close](#)

[Quit](#)

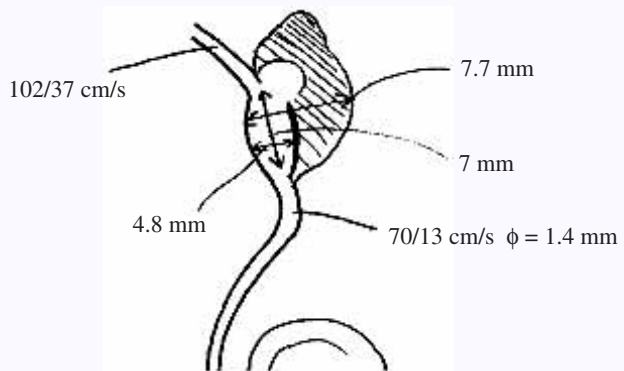


Fig. 1. A vascular technologist's impression of the STA pseudoaneurysm.

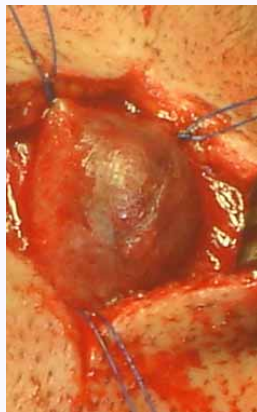


Fig. 2. Intra-operative photograph of the exposed STA pseudoaneurysm. The proximal STA and two distal branches are seen here (ligated).

Abstract

Keywords

Case report

Diagnosis

Discussion

Teaching point

References

Figure 1

Figure 2

Home Page

Title Page



Go Back

Full Screen

Close

Quit

Discussion

Among the 200 or so cases of STA aneurysm reported in the world literature, more than 95% have been traumatic. Of these, the majority are due to blunt injuries, including sporting. Furthermore, iatrogenic causes have more recently been described, following craniotomy, temporomandibular joint surgery and hair transplantation. Only the remaining 5% are true congenital and atherosclerotic aneurysms^[2]. The STA, after originating from the external carotid artery at the base of the parotid gland, runs a relatively exposed course over the temporal bone. Hence, one might expect more injuries to the vessel than have been reported^[3]. The frontal branch of the artery is more vulnerable to trauma at the level of the temporal line. An arteriovenous fistula may also develop because of involvement of the satellite vein^[4]. With regards demographics, young men are the most commonly affected group, although the condition has been described in older individuals as a complication of falls^[5].

The pathophysiology is of either a partial transection of the artery, or severe contusion and necrosis of a sector of the arterial wall. The intact overlying skin confines the resultant haemorrhage. The haematoma becomes progressively organised such that a fibrous pseudocapsule forms. Continual lysis and resorption of luminal thrombus means that the artery may become recanalised, permitting substantial reflow through the vessel. This continued flow through the artery and into the pseudoaneurysm sac causes progressive dilation of the weak haematoma capsule.

The usual presenting symptom is of a pulsating swelling in the temporal region or a throbbing headache. Less commonly, audible pulsation, ear discomfort, visual disturbances, dizziness and focal neurology associated with bony fracture and/or middle meningeal artery damage causing aneurysm or extradural haematoma. Pulsation is present in many cases, but may be absent in those where the sac is filled with thrombosis. A continuous thrill or bruit suggests arteriovenous fistula. Compression of the proximal STA can result in diminution or cessation of pulsation of the STA aneurysm, but not in a vascular tumour or middle meningeal artery aneurysm. Index of suspicion is raised if there is gradual expansion of the lesion. The most accurate non-invasive imaging modality

Abstract

Keywords

Case report

Diagnosis

Discussion

Teaching point

References

Figure 1

Figure 2

Home Page

Title Page

◀▶

◀▶

Go Back

Full Screen

Close

Quit

GR

is a duplex ultrasound scan of the lesion, which shows the native vessel, with a fusiform dilatation consistent with the mass, and the presence of turbulent intraluminal blood flow.

Although observation, prolonged compression and embolisation have been employed, operative intervention is indicated to relieve symptoms, to correct the deformity and to prevent rupture. This latter complication can rarely occur, spontaneously^[6], or from subsequent head trauma or skin erosion. Successful endovascular obliteration of the STA aneurysm has been reported. However, ligation of the afferent and efferent vessels, with excision of the aneurysm, under local or general anaesthesia, remains the treatment of choice. No specific follow-up is necessary as recurrence very rare.

Teaching point

Pseudoaneurysm of the superficial temporal artery is a rare consequence of head injury, particularly blunt, with iatrogenic causes being documented increasingly. Diagnosis is primarily clinical, with management planned using imaging techniques, of which we recommend duplex ultrasonography. Surgical excision yields excellent results.

References

1. Pipinos II, Dossa CD, Reddy DJ. Superficial temporal artery aneurysms. J Vasc Surg 1998; 27: 374-7. [MEDLINE Abstract](#)
2. Lozman H, Nussbaum M. Aneurysm of the superficial temporal artery. Am J Otolaryngol 1982; 3: 376-8. [MEDLINE Abstract](#)
3. Bailey IC, Kiryabwire JW. Traumatic aneurysms of the superficial temporal artery. Br J Surg 1973; 60: 530. [MEDLINE Abstract](#)
4. Guida PM, Moore SW. Aneurysms and arteriovenous fistulas of the temporal artery. Am J Surg 1968; 115: 825-7. [MEDLINE Abstract](#)
5. Cremonese JC, Grosh JD. Traumatic aneurysms of the superficial temporal artery. J Trauma 1980; 20: 986-8. [MEDLINE Abstract](#)

[Abstract](#)

[Keywords](#)

[Case report](#)

[Diagnosis](#)

[Discussion](#)

[Teaching point](#)

[References](#)

[Figure 1](#)

[Figure 2](#)

[Home Page](#)

[Title Page](#)



[Go Back](#)

[Full Screen](#)

[Close](#)

[Quit](#)

6. Sharma A, Tyagi G, Sahai A, Bajjal SS. Traumatic aneurysm of the superficial temporal artery: CT demonstration. *Neuroradiology* 1991; 33: 510-2. [MEDLINE Abstract](#)

[Abstract](#)

[Keywords](#)

[Case report](#)

[Diagnosis](#)

[Discussion](#)

[Teaching point](#)

[References](#)

[Figure 1](#)

[Figure 2](#)

[Home Page](#)

[Title Page](#)



[Go Back](#)

[Full Screen](#)

[Close](#)

[Quit](#)