

# Metastatic prostate cancer presenting with hoarseness\*

Irina Rybalova<sup>†||</sup>, Claudia F. E. Kirsch<sup>‡||</sup>, Jin K. Choe<sup>§||</sup>  
and Basil S. Kasimis<sup>¶||</sup>

<sup>†</sup>*Department of Medical Oncology and Hematology, Albert Einstein College of Medicine, Montefiore Medical Center, 111 East 210th Street, Bronx, New York 10467-2490, USA*

<sup>‡</sup>*Royal London Hospital and Bartholomew's Hospital, Flat 17 Eyre Court, 3-21 Finchley Road, London, NW8 9TT, UK*

<sup>§</sup>*Department of Pathology, VA New Jersey Health Care Systems, 385 Tremont Avenue, East Orange, New Jersey 07018, USA*

<sup>¶</sup>*Department of Medical Oncology, VA New Jersey Health Care Systems, 385 Tremont Avenue, East Orange, New Jersey 07018, USA*

<sup>||</sup>*Department of Medical Oncology, Radiology and Pathology, VA New Jersey Health Care Systems, East Orange, New Jersey, USA*

Date accepted for publication 8 February 2005

\*This case has been prepared for publication as a collaborative work of the above physicians who were involved in the care of this patient at the VA Hospital, East Orange, New Jersey.

[Abstract](#)

[Keywords](#)

[Introduction](#)

[Case report](#)

[Discussion](#)

[Teaching point](#)

[Conclusion](#)

[References](#)

[Figure 1](#)

[Figure 2](#)

[Home Page](#)

[Title Page](#)

[◀◀](#) [▶▶](#)

[◀](#) [▶](#)

[Go Back](#)

[Full Screen](#)

[Close](#)

[Quit](#)

GR

## Abstract

Metastatic involvement resulting in voice alteration may occur from vocal cord infiltration or recurrent laryngeal nerve involvement. We present a case of metastatic prostate adenocarcinoma to the left infrahyoid neck compressing the larynx resulting in hoarseness. A case report with one-year follow-up is presented. The patient is a 65-year-old male with hoarseness and a left infrahyoid prostate metastases measuring 8 by 10 cm, effacing the left pyriform sinus and shifting the true and false vocal cords to the right of midline, with cord morphology and mobility maintained. Definitive radiation therapy reduced the infrahyoid metastases with resolution of hoarseness. Phonatory alteration from metastatic prostate carcinoma is rare. We present a case of hoarseness resulting from displacement of the larynx from infrahyoid metastases, which resolved after reduction in size of the metastases with radiation therapy.

## Keywords

Prostate cancer; laryngeal compression; hoarseness.

## Introduction

Laryngeal involvement by malignant neoplasms arising in contiguous structures and secondary infiltration by leukemia and lymphoma is well reported. Less well described are laryngeal metastases from remote primaries including urogenital tract malignancies. In a series of 845 patients with metastatic carcinomas of the urogenital tract, 1.5% of patients developed metastases to the head and neck of prostate origin<sup>[1]</sup>. Prostate carcinoma typically metastasizes to bone and lymph nodes with visceral involvement occurring later in the disease course. A review of the English literature identified nine cases of laryngeal metastases from prostate carcinoma. Five of these patients developed phonatory changes from either recurrent laryngeal nerve involvement or tumoral invasion.

[Abstract](#)[Keywords](#)[Introduction](#)[Case report](#)[Discussion](#)[Teaching point](#)[Conclusion](#)[References](#)[Figure 1](#)[Figure 2](#)[Home Page](#)[Title Page](#)[◀◀](#)[▶▶](#)[◀](#)[▶](#)[Go Back](#)[Full Screen](#)[Close](#)[Quit](#)

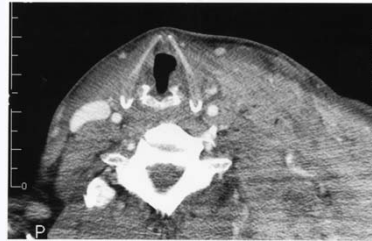
We report a case of hoarseness resulting from a prostate adenocarcinoma metastases to the left infrahyoid region measuring 8 by 10 cm. The prostate metastases infiltrated the left sternocleidomastoid muscle, and effaced the left pyriform sinus. Although the mass displaced the true and false cords to the right of midline, the cord morphology and mobility were maintained. The hoarseness and phonatory changes resulted from compression and displacement of the larynx and resolved after a reduction in size of the metastases from radiation therapy.

## Case report

A 65-year-old man presented with scrotal edema and an enlarging left neck mass. Initial physical examination was remarkable for a painless, hard, nodular, fixed left infrahyoid neck mass measuring 8 by 10 cm in size. Pelvic examination revealed penile and scrotal edema. The rectal examination revealed a hard nodular prostate gland. Transrectal needle biopsy demonstrated poorly differentiated prostate adenocarcinoma, Gleason score 7 with bilateral extracapsular and perineural invasion. The initial prostate-specific antigen (PSA) level was 138.5 ng/ml. A left neck mass biopsy revealed metastatic prostate cancer. Abdominal computerized axial tomography (CT) showed extensive retroperitoneal lymphadenopathy and mild left hydronephrosis. The radionuclide bone scan was unremarkable and the patient was staged as a D2 prostate cancer. He was initially treated with bicalutamide 50 mg orally, followed by goserelin 10.8 mg depot injections every 3 months. The hormonal therapy led to a decrease in size of the left neck mass, resolution of the pelvic lymphadenopathy, hydronephronephrosis and scrotal edema, and decrease in PSA to 7.1 ng/ml.

Nine months after initial diagnosis, the patient returned complaining of recurrent voice changes and regrowth of the left neck mass. Repeat physical examination revealed a large fixed, hard, non-tender left neck mass extending from the submandibular region to the supraclavicular area anteriorly and to the upper border of the left trapezius muscle posteriorly. Repeat biopsy of the neck mass confirmed metastatic adenocarcinoma,

[Abstract](#)[Keywords](#)[Introduction](#)[Case report](#)[Discussion](#)[Teaching point](#)[Conclusion](#)[References](#)[Figure 1](#)[Figure 2](#)[Home Page](#)[Title Page](#)[◀◀](#)[▶▶](#)[◀](#)[▶](#)[Go Back](#)[Full Screen](#)[Close](#)[Quit](#)



**Fig. 1.** The microphotography shows a prostatic acid phosphatase (PAP) positive (red cytoplasmic stain), metastatic prostate adenocarcinoma in the skin (200 $\times$ , immunohistochemistry stain for PAP).

consistent with prostatic primary (Fig. 1). Immunohistochemistry stains were strongly positive for both PSA and prostatic acid phosphatase (PAP). The PSA had increased to 58 ng/ml. The neck CT (Fig. 2) revealed an extensive mass infiltrating the fixed left sternocleidomastoid muscle with complete obliteration of the left internal jugular vein. The mass displaced the laryngeal cartilage, arytenoids and false and true cords to the right of midline with preservation of the anterior commissure. Components of the mass abutted and effaced the inferior aspect of the left pyriform sinus with preservation of the aryepiglottic folds. Indirect laryngoscopy revealed mobile vocal cords and normal laryngeal mucosa. The new onset of hoarseness prompted a speech pathology evaluation, confirming phonatory changes attributed to direct compression of the larynx and alteration of the laryngeal space by the tumor. The patient received a course of radiation therapy (RT) to the neck mass of 5400 cGy. There was partial response of the mass to RT with complete restoration of voice quality.

## Discussion

Prostate cancer is the most common cancer in men in many western countries, and is the second leading cause of cancer deaths in men. The most common sites of metastases

[Abstract](#)

[Keywords](#)

[Introduction](#)

[Case report](#)

**[Discussion](#)**

[Teaching point](#)

[Conclusion](#)

[References](#)

[Figure 1](#)

[Figure 2](#)

[Home Page](#)

[Title Page](#)

◀◀ ▶▶

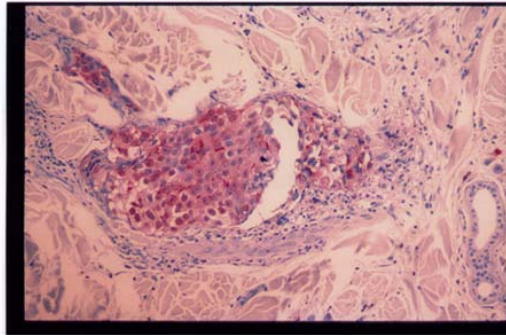
◀ ▶

[Go Back](#)

[Full Screen](#)

[Close](#)

[Quit](#)



**Fig. 2.** Axial post-contrast CT scan of the neck demonstrates an extensive metastatic lesion infiltrating the left sternocleidomastoid muscle displacing the laryngeal cartilage, arythenoids and true vocal cords to the right of midline.

are bone and regional lymph nodes with reports of 66.8% and 68%, respectively, in autopsied cases. Additional frequent sites of metastatic involvement include lung (49.1%), bladder (39.2%), liver (35.6%), and adrenals (17.3%)<sup>[2]</sup>. Head and neck metastases are uncommon, comprising only 3.2% of all cases of metastatic adenocarcinoma of the prostate<sup>[1]</sup>. The majority of prostatic metastases to the head and neck are to supraclavicular nodes or bony structures. Laryngeal metastases from primary prostate carcinoma are unusual, representing only 6% of all laryngeal metastases<sup>[2]</sup>. Malignancies more commonly metastasizing to the larynx in order of frequency include: malignant melanoma (30% of all cases), renal cell carcinoma (16.9%), breast (9.6%) and lung carcinoma (9.8%)<sup>[3]</sup>. A review of the English literature (MEDLINE search 1966–2005) identified nine cases of laryngeal metastasis from prostate carcinoma.

The first case of laryngeal metastasis was reported by Erlich in 1954<sup>[4]</sup>. He described a 70-year-old patient with diffuse metastatic prostate carcinoma who incidentally at autopsy had metastatic disease in the cricoid and thyroid cartilages.

[Abstract](#)

[Keywords](#)

[Introduction](#)

[Case report](#)

**[Discussion](#)**

[Teaching point](#)

[Conclusion](#)

[References](#)

[Figure 1](#)

[Figure 2](#)

[Home Page](#)

[Title Page](#)

◀ ▶

◀ ▶

[Go Back](#)

[Full Screen](#)

[Close](#)

[Quit](#)

Quinn and McCabe reported two cases including an 83-year-old man presenting with pain in the left throat radiating to the left ear in 1957<sup>[5]</sup>. A 1-cm mass on the upper surface of the left arytenoid eminence was pathologically confirmed to be a “papilliferous adenocarcinoma”. A subsequent prostatic biopsy was suggestive of adenocarcinoma. The second patient was a 74-year-old man with increasing hoarseness and mass involving the thyroid cartilage. ENT exam revealed a tumor involving the thyroid cartilage bilaterally. The prostate gland was believed to be clinically carcinomatous, and subsequent biopsy of the neck mass revealed adenocarcinoma.

In 1984, Coakly and Ranson reported a fourth case of symptomatic metastasis to the larynx<sup>[6]</sup>. In their case, a 64-year-old male developed stridor 6 months after the histologic diagnosis of prostate adenocarcinoma. Indirect laryngoscopy revealed an annular, smooth subglottic mass pathologically similar to the primary lesion. Batsakis *et al.*<sup>[3]</sup> added a fifth case of prostatic laryngeal metastasis without providing details of the case.

In 1986 Hessian *et al.*<sup>[1]</sup> presented a 70-year-old male with a mass overlying the right thyroid ala producing cartilage erosion and laryngeal ventricle obliteration resulting in adenocarcinoma, presumably of thyroid origin. Fourteen months later the patient died with widespread metastases. A retrospective review of the autopsy specimen using PSA proved the original tumor to be a prostate adenocarcinoma.

In 1990, Crignon *et al.*<sup>[7]</sup> described a 71-year-old man with known prostate adenocarcinoma and bone metastases who developed hoarseness 16 months after initial diagnosis. Biopsy of the swollen right true vocal cord revealed the appearance of a small cell carcinoma without glandular differentiation. The initial prostatic tissue was shown to be a tumor with foci of mixed small cell carcinoma-adenocarcinoma histology.

The case reported by Park and Park<sup>[8]</sup> in 1993 was the first case of dysphonia from vocal cord paralysis caused by recurrent laryngeal nerve palsy from a mass involving the thyroid cartilage. The patient was diagnosed with prostate cancer 9 years prior to the discovery of the laryngeal abnormalities.

An additional case of hoarseness secondary to the left recurrent laryngeal nerve palsy was described by Old<sup>[9]</sup> in 1999. He reported a case of a 68-year-old male who developed massive mediastinal and cervical lymphadenopathy 3 years after the diagnosis of prostate

[Abstract](#)[Keywords](#)[Introduction](#)[Case report](#)[Discussion](#)[Teaching point](#)[Conclusion](#)[References](#)[Figure 1](#)[Figure 2](#)[Home Page](#)[Title Page](#)[◀◀](#)[▶▶](#)[◀](#)[▶](#)[Go Back](#)[Full Screen](#)[Close](#)[Quit](#)

**Table 1: Summary of nine cases of prostate carcinoma metastatic to the larynx.**

Case	Author, year	Age (years)	Phonetary changes	Mechanism of voice distortion	Other local symptoms	Site of laryngeal metastases	Other systemic metastases	Time from diagnosis to development of phonetary changes
1	Erlich, 1954 <sup>[4]</sup>	70	NR <sup>a</sup>	-	None	Thyroid and cricoid cartilage	Bone, liver, lungs, adrenals	NA
2	Quinn/McCabe, 1957 <sup>[5]</sup>	83	NR	-	Pain, left side of the throat, radiating to the left ear	Left arythenoid eminence	NR	NA
3	Quinn/McCabe, 1957 <sup>[5]</sup>	74	Hoarseness ×12 months	? Infiltration of the left true vocal cord by the tumor	Midanterior cervical mass	Thyroid cartilage, left true vocal cord	NR	Hoarseness preceded the diagnosis by 12 months
4	Coakley/Ranson, 1984 <sup>[6]</sup>	64	NR	-	Stridor	Subglottic	Bone	NA
5	Batsakis <i>et al.</i> , 1984 <sup>[3]</sup>	NR	NR	-	NR	NR	NR	NR
6	Hessan <i>et al.</i> , 1986 <sup>[1]</sup>	70	Hoarseness	Obliteration of the laryngeal ventricle	Mass overlying the right thyroid ala	Thyroid cartilage	None reported at time of diagnosis	Hoarseness preceded the diagnosis by 5 months
7	Grignon <i>et al.</i> , 1990 <sup>[7]</sup>	71	Hoarseness	Vocal cord infiltration	None	Right true vocal cord	Bone	16 months
8	Park/Park, 1993 <sup>[8]</sup>	66	Hoarseness	Left vocal cord paralysis from recurrent laryngeal nerve palsy	None	Thyroid cartilage	Bone	9 years
9	Old, 1999 <sup>[9]</sup>	68	Hoarseness	Left recurrent laryngeal nerve palsy	Superior vena cava syndrome (developed 4 months after onset of hoarseness)	Left hemi-larynx	Para-aortic, pelvic, and mediastinal lymphadenopathy	24 months
10	Current case, 2004	65	Hoarseness	Compression and displacement of larynx by the tumor	Extensive left neck mass	None	Retroperitoneal lymphadenopathy	9 months

<sup>a</sup>NR, not reported; NA, not available.

[Abstract](#)
[Keywords](#)
[Introduction](#)
[Case report](#)
[Discussion](#)
[Teaching point](#)
[Conclusion](#)
[References](#)
[Figure 1](#)
[Figure 2](#)
[Home Page](#)
[Title Page](#)


[Go Back](#)
[Full Screen](#)
[Close](#)
[Quit](#)

cancer. This resulted in superior vena cava obstruction as well as the left recurrent laryngeal nerve palsy. Clinical details of the reported cases are summarized in Table 1.

In our case, a 65-year-old man with known adenocarcinoma of the prostate with extensive retroperitoneal adenopathy and left neck metastasis developed a new onset of hoarseness 9 months after the initial diagnosis. Repeat biopsy of the left neck mass confirmed metastatic adenocarcinoma, consistent with prostatic primary. The mass directly compressed and displaced the laryngeal structures without evidence of invasion, resulting in displacement of the true and false vocal cords. On endoscopic examination the vocal cords were mobile and the laryngeal mucosa was intact.

Detailed case analysis revealed that phonatory changes resulting from laryngeal metastases may be caused by tumor infiltration with laryngeal obliteration<sup>[1]</sup>, dysphonia from vocal cord infiltration<sup>[5,7]</sup> or paralysis due to involvement of the recurrent laryngeal nerve by the metastatic tumor<sup>[8,9]</sup>. In four case reports, the prostatic metastases to the larynx were not associated with phonatory changes<sup>[3-6]</sup>.

Neoplastic spread to the larynx may be either contiguous, hematogenous or lymphatic. The vascular spread through the vena cava may then enter the right heart and pulmonary circulation returning to the left heart and then up to the aorta and laryngeal artery<sup>[10]</sup>. Dissemination through lung passage usually happens later in the disease. Hematogenous spread may also be retrograde through the vertebral venous plexus, as suggested by Batson more than 50 years ago<sup>[11]</sup>. Retrograde spread from the prostate to the lower spine usually occurs early in the disease. In a similar manner, lymphatic spread may follow an orderly cascade or be retrograde via anastomoses.

The finding of metastases in the larynx nearly always signifies a terminal stage of the disease and is associated, in most instances, with widespread dissemination<sup>[12]</sup>. On rare occasions the laryngeal metastasis may be the only clinical evidence of spread from the primary.

[Abstract](#)

[Keywords](#)

[Introduction](#)

[Case report](#)

[Discussion](#)

[Teaching point](#)

[Conclusion](#)

[References](#)

[Figure 1](#)

[Figure 2](#)

[Home Page](#)

[Title Page](#)

◀◀ ▶▶

◀ ▶

[Go Back](#)

[Full Screen](#)

[Close](#)

[Quit](#)

## Teaching point

In patients presenting with signs and symptoms of laryngeal involvement, one should remember not only that the most common cause is malignant disease of the chest and head and neck, but also the fact that distant metastases can cause phonatory symptoms. In the majority of cases, histological differentiation is not difficult because the primary tumor has usually been characterized. However, if the primary site is unknown, one should consider other tumors at risk for spread to the larynx, such as malignant melanoma, renal cell carcinoma, breast and lung neoplasms<sup>[3]</sup>. Our case reinforces the recommendation that prostate carcinoma should be considered in men more than 45 years of age with metastatic carcinoma of the head and neck. Therefore, evaluation should include immunohistochemical studies and appropriate urologic and pathologic consultation.

## Conclusion

Although extremely rare, a few cases of prostate carcinoma metastatic to the larynx with secondary voice changes have been reported. This case represents the only example of hoarseness resulting from metastatic prostate adenocarcinoma compressing and displacing the larynx.

## References

1. Hessian H, Strauss M, Sharkey FE. Urogenital tract carcinoma metastatic to the head and neck. *Laryngoscope* 1986; 96: 1352-6. [MEDLINE Abstract](#)
2. Saitoh H, Hida M, Shimbo T, Nakamura K, Yamagata J, Satoh T. Metastatic patterns of prostatic cancer. *Cancer* 1984; 54: 3078-84. [MEDLINE Abstract](#)
3. Batsakis JG, Luna MA, Byers RM. Metastases to the larynx. *Head Neck Surg* 1985; 7: 458-60. [MEDLINE Abstract](#)

[Abstract](#)[Keywords](#)[Introduction](#)[Case report](#)[Discussion](#)[Teaching point](#)[Conclusion](#)[References](#)[Figure 1](#)[Figure 2](#)[Home Page](#)[Title Page](#)[◀◀](#)[▶▶](#)[◀](#)[▶](#)[Go Back](#)[Full Screen](#)[Close](#)[Quit](#)

4. Erlich A. Tumor involving the laryngeal cartilages. Arch Otolaryngol 1954; 59: 178-85.
5. Quinn FB Jr, McCabe BF. Laryngeal metastasis from malignant tumors in distant organs. Ann Otol Rhinol Laryngol 1957; 66: 139-43. [MEDLINE Abstract](#)
6. Coakley JF, Ranson DL. Metastasis to the larynx from a prostate carcinoma: a case report. J Laryngol Otol 1984; 98: 839-42. [MEDLINE Abstract](#)
7. Grignon DJ, Ro JY, Ayala AG, Chong C. Carcinoma of prostate metastasizing to vocal cord. Urology 1990; 36: 85-8. [MEDLINE Abstract](#)
8. Park YW, Park MH. Vocal cord paralysis from prostatic carcinoma metastasizing to the larynx. Head Neck 1993; 15: 455-8. [MEDLINE Abstract](#)
9. Old SE. Superior vena cava obstruction in prostate cancer. Clin Oncol 1999; 11: 352-4.
10. Ferlito A, Caruso G. Secondary malignant melanoma of the larynx. Report of two cases and review of 79 laryngeal secondary cases. ORL J Otorhinolaryngol Relat Spec 1984; 46: 117-33. [MEDLINE Abstract](#)
11. Batson OV. The function of the vertebral veins and their role in the spread of metastases. Ann Surg 1940; 112: 138-49.
12. Batsakis JG. The pathology of the head and neck tumors: the occult primary and metastases to the head and neck, part 10. Head Neck Surg 1981; 3: 409-23. [MEDLINE Abstract](#)

[Abstract](#)

[Keywords](#)

[Introduction](#)

[Case report](#)

[Discussion](#)

[Teaching point](#)

[Conclusion](#)

[References](#)

[Figure 1](#)

[Figure 2](#)

[Home Page](#)

[Title Page](#)

◀◀ ▶▶

◀ ▶

[Go Back](#)

[Full Screen](#)

[Close](#)

[Quit](#)