

Grand Rounds Vol 4  
Speciality: general surgery; hepatology; gastroenterology  
Article Type: Case Report  
DOI: 10.1102/1470-5206.2004.0005  
© 2004 e-MED Ltd

# Spontaneous biliary peritonitis: two unusual cases

MG Berry<sup>†</sup> and James T. Allardice

*Department of General Surgery, The General Hospital, St Helier, Jersey, JE1 3QS, UK*

*<sup>†</sup> Current appointment: Specialist Registrar, Royal Preston Hospital, Preston, PR2 9HT, UK*

Date accepted for publication 30 August 2004

## Abstract

Two patients with biliary peritonitis without demonstrable perforation are described. Despite biliary peritonitis almost invariably following biliary tract perforation, none could be identified with contemporary imaging. This condition is extremely rare, difficult to diagnose pre-operatively and has high mortality.

## Keywords

Biliary peritonitis; spontaneous perforation; perforation-free.

Abstract

Keywords

Clinical history: case 1

Clinical history: case 2

Discussion

Lesson

References

Figure 1

Figure 2

Home Page

Title Page



Go Back

Full Screen

Close

Quit

# GR

## Clinical history: case 1

A woman of 56 years presented with acute painful jaundice (bilirubin 44  $\mu\text{mol/l}$ ) and generalised peritonitis. Amylase was normal and no pneumoperitoneum was demonstrable radiographically. Ultrasound scan showed extensive intraperitoneal free fluid, a dilated (9 mm) common bile duct (CBD), but no intraductal calculi. Two litres of bile were aspirated at laparotomy, but no biliary leak was found despite dissection of the gall bladder, CBD and cystic duct. Percutaneous transhepatic cholangiography (PTC) demonstrated dilated ducts with a large CBD calculus (Fig. 1), but no biliary leak despite continued abdominal bile drainage. The patient made good progress, but suffered a sudden mortal cardiorespiratory arrest at 2 weeks; post-mortem was refused.

## Clinical history: case 2

A 64-year-old year woman, awaiting cholecystectomy for symptomatic gallstones, presented with acute cholecystitis. Leucocytes were raised ( $12.1 \times 10^9/\text{l}$ ) as were bilirubin (75  $\mu\text{mol/l}$ ), alkaline phosphatase (368 IU/l),  $\gamma$ -glutamyl transferase (434 IU/l) and alanine aminotransferase (567 IU/l); amylase was 60 U/dl. Generalised peritonitis supervened after 3 days and laparotomy revealed biliary peritonitis. Extra-hepatic biliary tree dissection failed to demonstrate any perforation, but a large gallbladder neck-impacted calculus produced type I Mirizzi syndrome. Following cholecystectomy, histopathological examination confirmed inflammation, but no perforation. Bile, up to 800 ml daily, continued to drain and 2,6-dimethylphenyl-carbamoylmethyliminodiacetic acid (HIDA) scan failed to localise the leak (Fig. 2). Endoscopic retrograde cholangiopancreatogram (ERCP) showed a small CBD calculus, but again no leak. Five days after stenting, the drainage ceased and full recovery occurred; the calculus was crushed at subsequent ERCP. She remained well on early outpatient review, but became lost to follow up.

Abstract

Keywords

Clinical history: case 1

Clinical history: case 2

Discussion

Lesson

References

Figure 1

Figure 2

Home Page

Title Page



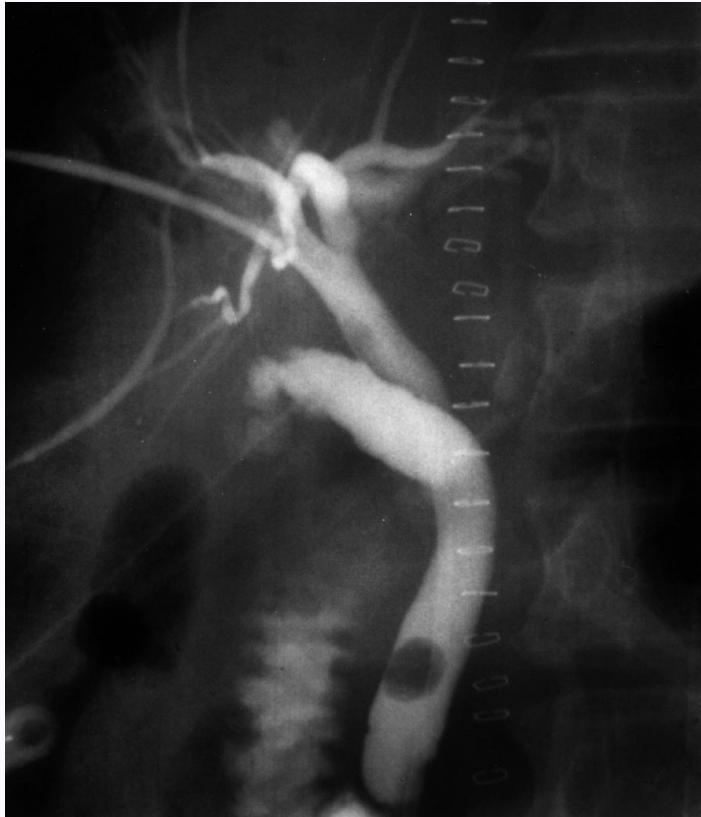
Go Back

Full Screen

Close

Quit





**Fig. 1.** Percutaneous trans-hepatic cholangiogram demonstrating dilated biliary tree with common bile duct calculus in case 1, but no contrast leak.

*Abstract*

*Keywords*

*Clinical history: case 1*

*Clinical history: case 2*

*Discussion*

*Lesson*

*References*

[Figure 1](#)

[Figure 2](#)

[Home Page](#)

[Title Page](#)



[Go Back](#)

[Full Screen](#)

[Close](#)

[Quit](#)

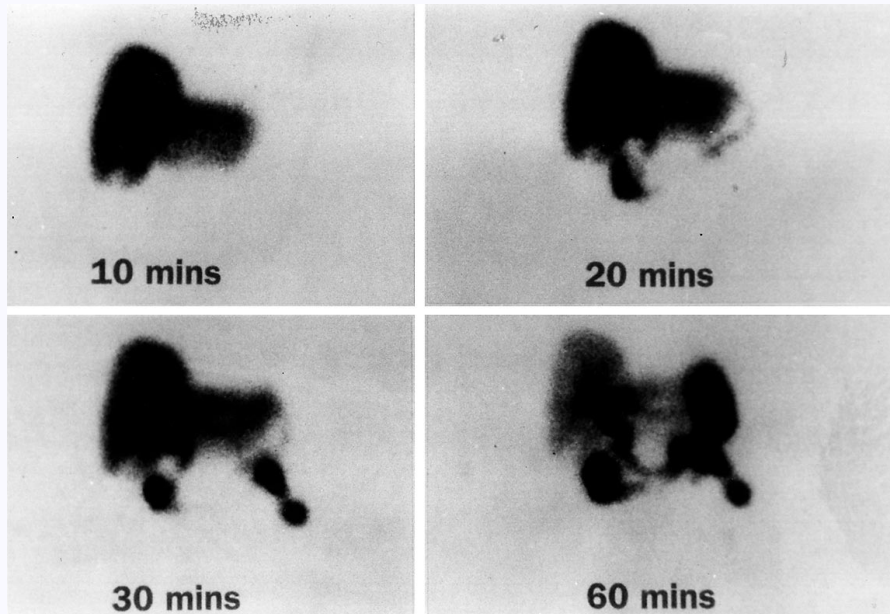


Fig. 2. HIDA scan demonstrating the absence of biliary tree leak in the second case.

## Discussion

Biliary peritonitis most commonly follows biliary tract puncture following surgery, trauma or instrumentation. Spontaneous biliary peritonitis (SBP) is rare and has no evident precipitants; a 1912 review concluded that all 108 cases studied resulted from perforation<sup>[1]</sup>. Yet less frequently seen is SBP without identifiable perforation; the first such case was reported in 1905<sup>[2]</sup>. Explanations of bile escape from apparently imperforate

Abstract

Keywords

Clinical history: case 1

Clinical history: case 2

Discussion

Lesson

References

Figure 1

Figure 2

Home Page

Title Page

◀◀

▶▶

◀

▶

Go Back

Full Screen

Close

Quit

GR

biliary tracts include bile ‘transudation’ across ducts in association with CBD obstruction<sup>[3]</sup> or solubilisation of normally impermeable bile by trypsin liberated during mild/subacute pancreatitis<sup>[4]</sup>; in neither of our cases was the amylase elevated. Others have suggested a pressure-related leak, through perforations invisible to the naked eye<sup>[5]</sup>, however, PTC, ERCP and HIDA all failed to demonstrate any leakage despite copious simultaneous abdominal bile drainage. In neither case was T-tube cholangiography performed due to the negative multi-modal imaging and potential for adversely affecting the patients’ clinical condition. It also seems improbable that so much bile could escape through microscopic orifices over so short a time. Furthermore, whereas generalised biliary peritonitis follows sudden, large perforations, small gradual leaks produce localised collections with microscopic breaches tending to close spontaneously following pressure release<sup>[6]</sup>.

## Lesson

These two cases emphasise the need to be aware of unusual presentations of the acute abdomen and highlight the fact that biliary peritonitis may present without macroscopic biliary system perforation in the extremely rare instance. In both patients, continued leakage of bile was observed via abdominal drains whilst contemporaneous biliary tree imaging demonstrated no leak so the precise aetiology of this rare, life-threatening condition remains enigmatic. Whilst our patients may have benefited from percutaneous drainage, as with a localised ‘biloma’<sup>[7]</sup>, perforation-free SBP is presently diagnosed only retrospectively and generalised peritonitis mandates laparotomy. Surgeons should be aware of the possible association of perforationless SBP with CBD calculi and give careful consideration to emergency pre-operative ERCP or per-operative T-tube placement.

## References

1. McWilliams CA. Acute, spontaneous perforation of the biliary system into the free peritoneal cavity. *Ann Surg* 1912; 55: 235-63.

*Abstract*

*Keywords*

*Clinical history: case 1*

*Clinical history: case 2*

*Discussion*

*Lesson*

*References*

*Figure 1*

*Figure 2*

*Home Page*

*Title Page*



*Go Back*

*Full Screen*

*Close*

*Quit*

2. Richardson MH. Trans Am Surg Assoc 1905; 23: 217-18.
3. Clairmont P, von Haberer H. Gallige Peritonitis ohne Perforation der Gallenwege. Mitt Grenzgeb Med Chir 1910; 22: 154-8.
4. Shanahan EF. Spontaneous biliary peritonitis. Br Med J 1961; 2: 154.
5. McLaughlin CW. Bile peritonitis. Ann Surg 1942; 115: 240-8.
6. Cope Z. Extravasation of bile. Br J Surg 1925; 13: 120-9.
7. Mason JC, Babbs C, Lee SH, Connolly MJ. Spontaneous biloma in an elderly patient. Postgrad Med J 1993; 69: 740-2. [MEDLINE Abstract](#)

[Abstract](#)[Keywords](#)[Clinical history: case 1](#)[Clinical history: case 2](#)[Discussion](#)[Lesson](#)[References](#)[Figure 1](#)[Figure 2](#)[Home Page](#)[Title Page](#)[Go Back](#)[Full Screen](#)[Close](#)[Quit](#)